

## Case Report

Access this article online

Quick Response Code:



Website:

[www.eurasianj pulmonol.com](http://www.eurasianj pulmonol.com)

DOI:

10.4103/ejop.ejop\_42\_18

# Submassive pulmonary thromboembolism as a first sign of occult adenocarcinoma

Fatma Yıldırım, Iskender Kara<sup>1</sup>, Halil Çınar<sup>2</sup>, Melda Türkoğlu<sup>3</sup>, Gülbin Aygencel<sup>3</sup>

### Abstract:

Venous thromboembolism is one of the most common complications of cancer, which also contributes to mortality in cancer patients. Venous thromboembolism can be observed as the first manifestation of occult cancer. We present the case of a 54-year-old woman with deep vein thromboembolism and pulmonary embolism as the first signs of cancer, who was subsequently diagnosed with disseminated adenocarcinoma, most likely originated from the pancreato-biliary system.

### Keywords:

Deep venous thrombosis, occult cancer, pancreas adenocarcinoma, pulmonary thromboembolism

## Introduction

It is well known that cancer is a risk factor for thromboembolic events. Among gastrointestinal cancers, pancreato-biliary system cancers have the highest risk of thromboembolic events. Pulmonary thromboemboli (PTE) and deep vein thrombosis (DVT) are the most common thromboembolic events associated with cancer. Thromboembolic events can occur during the course of various cancers and affect the prognosis of the disease. Association of thromboembolism at the time of diagnosis or before the diagnosis of cancer is very rare.<sup>[1-3]</sup>

Here, we report a case of pancreato-biliary system carcinoma diagnosed by lytic bone lesions, which was diagnosed as PTE and DVT with chest pain and shortness of breath.

## Case Report

A 54-year-old female patient with known hypertension, hypothyroidism,

and bilateral double-J catheter due to nephrolithiasis was admitted to our hospital with shortness of breath and chest pain for 3 days. She also had complaints of swelling and pain on her right leg for a week. On physical examination, her consciousness was clear, and orientation and co-operation were complete. Vital findings were as follows: heart rate: 106/min, blood pressure: 106/50 mmHg, respiratory rate: 28/min, and body temperature: 36.7°C. Respiratory sounds were decreased under the bilateral scapula on the pulmonary examination, and there was a 3-cm diameter increase on the right leg and Homans' sign was positive on the extremity examination. In the laboratory tests, we found the following: Hg: 8 gr/dL (12–15.5 gr/dL), white blood cell count: 12,670/mm<sup>3</sup> (4000–10,000/mm<sup>3</sup>), platelets: 238,000/mm<sup>3</sup> (150,000–400,000/mm<sup>3</sup>), and D-Dimer: 6811 mg/dL (<150 mg/dL). On transthoracic echocardiography, right heart cavities were wide and pulmonary arterial pressure (PAP) was high (systolic mean PAP = 54 mmHg). Thorax computed tomography (CT) angiography was performed with PTE suspicion. Filling defects compatible with thromboses in the

This is an open access journal, and articles are distributed under the terms of the Creative Commons Attribution-NonCommercial-ShareAlike 4.0 License, which allows others to remix, tweak, and build upon the work non-commercially, as long as appropriate credit is given and the new creations are licensed under the identical terms.

For reprints contact: [reprints@medknow.com](mailto:reprints@medknow.com)

**How to cite this article:** Yıldırım F, Kara I, Çınar H, Türkoğlu M, Aygencel G. Submassive pulmonary thromboembolism as a first sign of occult adenocarcinoma. *Eurasian J Pulmonol* 2018;20:107-10.

Intensive Care Unit, Dışkapı Yıldırım Beyazıt Research and Education Hospital, Clinic of Pulmonary Medicine, Health Sciences University, <sup>2</sup>Department of Internal Medicine, Faculty of Medicine, Gazi University, <sup>3</sup>Department of Internal Medicine, Internal Medicine Intensive Care Unit, Faculty of Medicine, Subdivision of Intensive Care, Gazi University, Ankara, <sup>1</sup>Intensive Care Unit, Konya Numune State Hospital, Clinic of Anesthesiology and Reanimation, Konya, Turkey

### Address for correspondence:

Dr. Fatma Yıldırım, Ankara Dışkapı Yıldırım Beyazıt Eğitim ve Araştırma Hastanesi 06550, Ankara, Turkey. E-mail: [ftagassi@hotmail.com](mailto:ftagassi@hotmail.com)

right main pulmonary artery and all lobar, segmental branches, left main pulmonary artery, and left lower lobe branches extending to the main pulmonary arteries were detected [Figure 1]. Bilateral lower-extremity venous Doppler ultrasonography showed thrombus formation in the right main, superficial femoral and popliteal venules in the lower right extremity. Lytic lesions were observed in all bone structures in thorax CT. Despite the presence of thrombus in both major pulmonary arteries and branches, PTE was thought to be subacute due to the clinic stability and normal blood pressure of the patient, and also lack of severe hypoxemia. Low-molecular-weight heparin (LMWH) 2 × 0.8 cc sc treatment was started because of the malignancy, presumably due to lytic lesions in the bones. Abdominal CT scan revealed heterogeneous-hypochoic multiple mass lesions, with the largest diameter 32 mm × 22 mm in the segment 5 of the liver. On upper gastrointestinal system endoscopy, extensive corpus and angulous erosions were observed and no significant mass lesion was detected. Increased <sup>18</sup>F-fluorodeoxyglucose uptakes were detected in multiple hypodense lesions with a largest diameter of 6.5 cm lesion in the liver (SUV<sub>max</sub>: 3,9); in celiac, para-aortic, aorticaval, periportal, bilateral external iliac lymph nodes (SUV<sub>max</sub>: 3,1); in the calvarium, in both mandibular rams, in multiple lytic sclerotic lesions of the pelvic bones; in the proximal sections of both humerus and femurs; in both clavicles and scapulae, in the vertebral column, and in the ribs of both hemithorax and sternum (SUV<sub>max</sub>: 5,6) [Figure 2]. There was no significant mass lesion indicating primary malignancy in the body of the patient. No gross mass lesion was found in thorax and abdominal CTs of the patient. In the cranial CT scan of the patient who had a seizure in the follow-up, hypodense lesion in the left frontal lobe that could be compatible with metastasis and edema was detected. Anticoagulant treatment of the patient was evaluated by neurosurgeon and intensive care team, and the patient received anti-edema and anti-epileptic treatments. A solid needle biopsy of lesion in the segment 5 of the liver was performed for primary cancer diagnosis. Pathologic diagnosis was determined as adenocarcinoma originating from the pancreato-biliary system. The patient was transferred

to the medical oncology department for evaluation in terms of chemotherapy.

Oral informed consent was obtained from the patient who participated in this study.

## Discussion

Here, we presented a case of occult pancreatic adenocarcinoma presenting with DVT and PTE, which could not be detected by abdominal CT or positron emission tomography/CT. Our patient had symptomatic DVT on the right lower limb and accompanying submassive PTE. DVT and PTE of patient were the first signs of the metastatic pancreatic adenocarcinoma with the multiple metastatic bone lesions and without a gross mass in the body.

Pancreatic cancer is the worst prognostic cancer type among the gastrointestinal cancers. Presenting signs are usually nonspecific and vary according to tumor size, localization, and stage of disease. The majority of tumors develop from the head of pancreas and present with blunt abdominal pain and obstructive jaundice. Rarely, gastrointestinal bleeding, deep or superficial venous thrombosis, gastrointestinal obstruction, or an increase around the abdomen may be seen. Jaundice, dystrophy in temporal muscles, peripheral lymphadenopathy, hepatomegaly, and acid can be detected in physical examination. Routine blood tests are usually nonspecific. Anemia, hyperglycemia, and impairment in liver tests may be found.<sup>[2]</sup> In our case, any gross tumoral formation was not detected in the pancreas and biliary system. Therefore, our patient did not have typical symptoms or signs of pancreatic tumors such as abdominal pain or

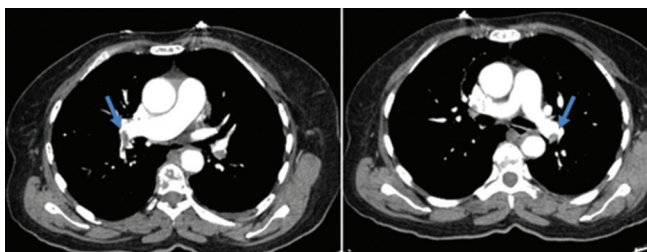


Figure 1: Thorax computed tomography scans showing thrombus formation in both main pulmonary arteries

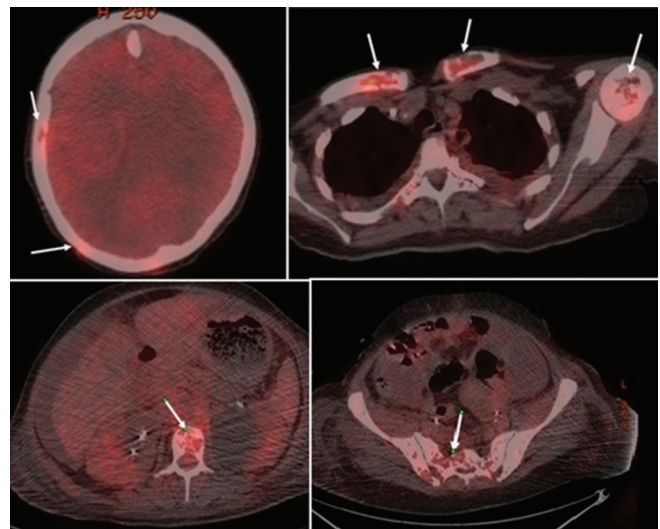


Figure 2: In positron emission tomography-computed tomography scans, there are multiple lytic lesions in myocardium, both clavicles, humeral head, vertebral column, and pelvis

obstructive jaundice. There was no evidence of bilirubin elevation or impairment in liver function tests in the laboratory findings to suggest pancreatic cancer.

Pancreatic cancer is the cancer type with the highest risk of PTE. Clinically, the incidence of VTE and pancreatic cancer has been reported between 5% and 26%.<sup>[3]</sup> Pancreatic cancer is associated with an increase in procoagulants such as tissue factor, thrombin, and fibrinogen. Increased expression of the tissue factor is associated with cancer-associated thrombosis, tumor angiogenesis, and growth. Hypercoagulabilization in pancreatic cancer enhances angiogenesis and also triggers inflammation and metastasis. For this reason, thromboembolism is a marker of high-grade metastatic pancreatic cancer, and it is emphasized that the prognosis is poor in malignancies with thrombosis as the first clinical symptom. Therefore, it is emphasized that the presence of thromboembolism is indicative of high-grade metastatic pancreatic cancer and that the prognosis is poor in malignancies in whom thrombosis is the first clinical symptom.<sup>[4-6]</sup> In our case, there was an advanced stage metastatic disease with metastases in all bones of the body and liver, and we lost our case on the 28<sup>th</sup> day of follow-up.

A retrospective study examining the risk factors for VTE in pancreatic cancer patients investigated 1115 pancreatic adenocarcinoma cases (54.5% metastatic disease). In multivariate analysis, the tumor location, absence of antithrombotic medication usage, blood group other than "O" blood group, and high body mass index were determined as independent risk factors. The probability of having a thromboembolic event in a pancreatic cancer patient who is including all of these four risk factors was reported to be 63.9%. When the analysis was limited to PTE and DVT, the presence of Hg below 10, obesity, metastatic tumor, tumor location, and type "A" and type "B" blood types were identified as independent risk factors for thromboembolic events. At the time of diagnosis, advanced stage is the strongest risk factor for VTE, and these patients have a 3.6-fold increased risk.<sup>[7]</sup> In our case, there were no risk factors other than malignancy that would trigger thromboembolism. She did not have any malignancy in her family story. Her blood group was "A" Rh (+). She did not use any antithrombotic treatment previously. Her body mass index was 29.3 kg/m<sup>2</sup> and her malignancy was in the metastatic stage.

Our case is a rare presentation of occult pancreatic cancer presenting with PTE and DVT. There are very few cases presenting with thromboembolism in literature.<sup>[8-10]</sup> In all of these cases, a pancreatic gross mass had been detected, but no mass was found in our case to suggest any malignancy in the pancreas or biliary system. We intended to share it with the literature because of the

occult pancreatic carcinoma and its presentation with VTE.

Treatment of cancer-related thromboembolism is a compelling situation for this group of patients due to a high risk for recurrent thromboembolism. Recently, LMWH has become the first choice because of its anticoagulant and antiangiogenic effects. Recently, a meta-analysis showed that LMWH is beneficial in pancreatic cancer patients to prevent DVT and PTE.<sup>[11]</sup> We prescribed LMWH to our patient for PTE treatment.

The prognosis of cancer patients with thromboembolism is poor. Larsen *et al.* investigated 121 patients with pancreato-biliary system cancer and they found that 12.4% (15/121) of patients had VTE at the time of diagnosis. Six of them were symptomatic VTE, while nine had incidental VTE. Survival of patients with VTE at the time of cancer diagnosis was shorter (median 4.4 months). There was no survival difference between the patients with symptomatic VTE and incidental VTE (3 vs. 5 months). VTE diagnosis after 1 month of cancer diagnosis significantly increased the mortality of patients with pancreato-biliary system.<sup>[12]</sup> Our patient with VTE at the time of her cancer diagnosis was died on 28<sup>th</sup> day of hospitalization.

### Declaration of patient consent

The authors certify that they have obtained all appropriate patient consent forms. In the form, the patient has given her consent for her images and other clinical information to be reported in the journal. The patient understand that her name and initials will not be published and due efforts will be made to conceal identity, but anonymity cannot be guaranteed.

### Financial support and sponsorship

Nil.

### Conflicts of interest

There are no conflicts of interest.

### References

1. Hidalgo M. Pancreatic cancer. *N Engl J Med* 2010;362:1605-17.
2. Khorana AA, Fine RL. Pancreatic cancer and thromboembolic disease. *Lancet Oncol* 2004;5:655-63.
3. Ryan DP, Hong TS, Bardeesy N. Pancreatic adenocarcinoma. *N Engl J Med* 2014;371:1039-49.
4. Nakchbandi IA, Löhr JM. Coagulation, anticoagulation and pancreatic carcinoma. *Nat Clin Pract Gastroenterol Hepatol* 2008;5:445-55.
5. Kasthuri RS, Taubman MB, Mackman N. Role of tissue factor in cancer. *J Clin Oncol* 2009;27:4834-8.
6. Mandalà M, Reni M, Cascinu S, Barni S, Floriani I, Ceredà S, *et al.* Venous thromboembolism predicts poor prognosis in irresectable pancreatic cancer patients. *Ann Oncol* 2007;18:1660-5.
7. Li D, Pise MN, Overman MJ, Liu C, Tang H, Vadhan-Raj S, *et al.*

Yıldırım, *et al.*: Pulmonary thromboembolism in occult adenocarcinoma

- ABO non-O type as a risk factor for thrombosis in patients with pancreatic cancer. *Cancer Med* 2015;4:1651-8.
8. Thapa SD, Hadid H, Usman M. Pulmonary embolism and stroke as the initial manifestation of advanced metastatic pancreatic adenocarcinoma. *J Gastrointest Cancer* 2015;46:182-4.
  9. Vlachostergios PJ, Oikonomou KG, Cheema MA, Apergis G. Saddle pulmonary embolism as the initial manifestation of pancreatic cancer. *Intern Med* 2015;54:687-8.
  10. Majumder S, Thom T, Dasanu CA. Catastrophic arteriovenous thromboembolism as initial manifestation of pancreatic cancer. *J Oncol Pract* 2012;13:231-4.
  11. Ben-Aharon I, Stemmer SM, Leibovici L, Shpilberg O, Sulkes A, Gafer-Gvili A, *et al.* Low molecular weight heparin (LMWH) for primary thrombo-prophylaxis in patients with solid malignancies—systematic review and meta-analysis. *Acta Oncol* 2014;53:1230-7.
  12. Larsen AC, Frøkjaer JB, Iyer VW, Fisker RV, Sall M, Yilmaz MK, *et al.* Venous thrombosis in pancreaticobiliary tract cancer: Outcome and prognostic factors. *J Thromb Haemost* 2015;13:555-62.