

Access this article online

Quick Response Code:



Website:
<https://eurasianjipulmonol.org>

DOI:
10.14744/ejp.2024.1004

A rare complication of sleeve gastrectomy: Gastro-bronchial fistula presenting as a pulmonary abscess

Merve Sarı Akyüz¹, Olgun Keskin¹, Nilay Çavuşoğlu Yalçın²

ORCID:

Merve Sarı Akyüz: 0000-0002-5537-2931

Olgun Keskin: 0000-0002-0995-7680

Nilay Çavuşoğlu Yalçın: 0000-0002-0675-9267

Abstract:

Bariatric surgery, specifically sleeve gastrectomy, is one of the fastest-growing areas within the surgical field. As with all evolving medical practices, it can lead to unexpected complications. One such rare and significant complication is a gastro-bronchial fistula, which typically results from anastomotic leakage. In most cases, antibiotic therapy is sufficient to manage this condition. The clinical presentation is often insidious, with patients remaining clinically stable. Here, we present the case of a 29-year-old female who required thoracotomy to treat a pulmonary abscess. This abscess was caused by a chronic leak from the sleeve gastrectomy staple line, occurring five years post-surgery.

Keywords:

Pulmonary abscess, gastrectomy, gastro-bronchial fistula

Introduction

Bariatric surgery is being performed with increasing frequency worldwide. Sleeve gastrectomy is a relatively new and evolving surgical technique, while Roux-en-Y gastric bypass remains the most common bariatric procedure globally. Sleeve gastrectomy has been gaining widespread popularity among both patients and surgeons due to its proven efficacy. The overall complication rate of sleeve gastrectomy ranges from 2.1% to 3%.^[1,2] The most common chronic complications of sleeve gastrectomy include gastroesophageal reflux disease and gastric stricture, whereas hem-

orrhage along the staple line and gastric fistula formation are the most prevalent acute adverse events.^[3] Early postoperative complications are generally manageable, but complications that arise months or years after surgery are often more complex and may require a multidisciplinary approach for effective management.

The incidence of gastric fistula following bariatric surgery has been estimated to be between 0.9% and 2.6%, whereas gastro-bronchial fistulas are exceedingly rare.^[4,5] A gastro-bronchial fistula can develop several months or even more than a year after a known leak from the staple line of

¹Department of Pulmonary Medicine, Antalya Training and Research Hospital, Antalya, Türkiye,

²Department of Thoracic Surgery, Antalya Training and Research Hospital, Antalya, Türkiye

Address for correspondence:

Dr. Merve Sarı Akyüz,
Department of Pulmonary Medicine, Antalya Training and Research Hospital, Antalya, Türkiye.
E-mail:
merve-sari@hotmail.com

Received: 27-04-2024

Revised: 14-06-2024

Accepted: 25-06-2024

Published: 22-01-2025

How to cite this article: Sarı Akyüz M, Keskin O, Çavuşoğlu Yalçın N. A rare complication of sleeve gastrectomy: Gastro-bronchial fistula presenting as a pulmonary abscess. Eurasian J Pulmonol 0000;00:1-4.

This is an open access journal, and articles are distributed under the terms of the Creative Commons Attribution-NonCommercial-ShareAlike 4.0 License, which allows others to remix, tweak, and build upon the work non-commercially, as long as appropriate credit is given and the new creations are licensed under the identical terms.

For reprints contact: kare@karepb.com



a sleeve gastrectomy, and it can become a life-threatening complication if left untreated. The management of gastro-bronchial fistula is challenging and requires a multidisciplinary approach, involving radiological, endoscopic, and surgical interventions. Here, we present the case of a 29-year-old female who developed a gastro-bronchial fistula and pulmonary abscess five years after undergoing sleeve gastrectomy.

Case Report

A 29-year-old female presented to the Emergency Department with complaints of a productive cough with brown-tinged sputum, hemoptysis, and fever for one week. She had consulted a pulmonologist and had been treated with antibiotics for symptoms of pneumonia. Her medical history included epilepsy and morbid obesity, for which she had undergone sleeve gastrectomy five years earlier. The surgical report indicated no adverse events, and her postsurgical recovery had been uneventful, with no comorbidities or complications. Additionally, she had undergone bilateral breast prosthesis surgery two months prior. Chest radiography was normal in the preoperative period before breast prosthesis surgery [Fig. 1a]. Chest examination revealed slight dullness in the left lower zone, decreased breath sounds in the left lower zone with bronchial breathing, and fine crackles. Diagnostic test results were as follows: white blood cell count (WBC): $8.9 \times 10^3 / \mu\text{L}$, C-reactive protein (CRP): 96.8 mg/L, hemoglobin (Hgb): 8.5 g/dL, and procalcitonin: 0.16 ng/mL.

The initial chest radiograph showed an increased density containing an air-fluid level in the left lower zone [Fig. 1b]. A follow-up computed tomography (CT) scan of the thorax revealed a 5 cm diameter cavitory mass lesion with thick walls and air-fluid densities in the left inferior lingular segment, along with accompanying consolidated areas [Fig. 1c-d]. A pulmonary abscess was suspected, and treatment with Ceftriaxone 2 g/day and Metronidazole 1.5 g/day was initiated. Due to the cavitory pattern of the lesion, a pulmonary CT angiography was performed to exclude septic embolism. Echocardiography, conducted to exclude valvular heart pathologies, showed no pathological findings. Abdominal ultrasound findings were completely normal. Bronchoscopy did not reveal any endobronchial lesions, but an abundant purulent secretion was observed from the left main bronchus. Bronchial lavage was negative for galactomannan, mycobacteria culture,

and acid-fast bacilli (AFB). Since *Pseudomonas putida* was isolated in the bacterial culture and *Candida glabrata* was isolated in the fungal culture, treatment was adjusted to Ceftazidime 6 g/day and Amphotericin B 200 mg/day. Despite undergoing medical treatment for approximately two months, there was no regression in the infection parameters, and radiological findings showed progression. The case was presented at the thoracic surgery council, where it was decided to perform a diagnostic and therapeutic thoracotomy for the pulmonary abscess.

She was scheduled for surgical management and repair. Upon making a left thoracotomy incision, tight pulmonary adhesions were observed. After releasing the adhesions and performing pulmonary decortication, the left lower lobe was identified and retracted upwards to dissect the cavitory lesion. The fistula tract was cut to separate the cavitory lesion from the diaphragm. Gastric contents with bile drainage into the pleural cavity were observed through a fistula tract in the diaphragm. The patient was consulted intraoperatively with general surgery. During a laparotomy, a leak was identified above the sleeve line at the esophago-gastric junction. Since this area was adjacent to the diaphragm, the diaphragm was perforated, and the fistula opened into the pleura, resulting in a pulmonary abscess. The pulmonary abscess was drained into the pleural cavity, and the gastric fistula and diaphragm were repaired. Unfortunately, the patient died 15 days post-surgery due to intra-abdominal sepsis during intensive care unit follow-up.

Discussion

For patients with obesity resistant to medical treatment, bariatric surgery has demonstrated superior outcomes in treating morbid obesity. The variety of surgical procedures performed to address obesity has significantly increased in recent years, accompanied by a rise in associated complications. Depending on the surgical approach utilized, the current complication rates range from 4% to 22%. Gastric fistula following bariatric surgery, in general, has an incidence of 0.9% to 2.6%.^[4] Specifically, gastro-bronchial fistula represents a rare yet serious complication of sleeve gastrectomy, with reported estimated rates ranging from 0.2% to 0.4% of all sleeve gastrectomies performed.^[5] Gastro-bronchial fistula typically arises from a subphrenic abscess. Chronic inflammation and infection may then propagate via lymphatic flow from below to above the diaphragm or directly

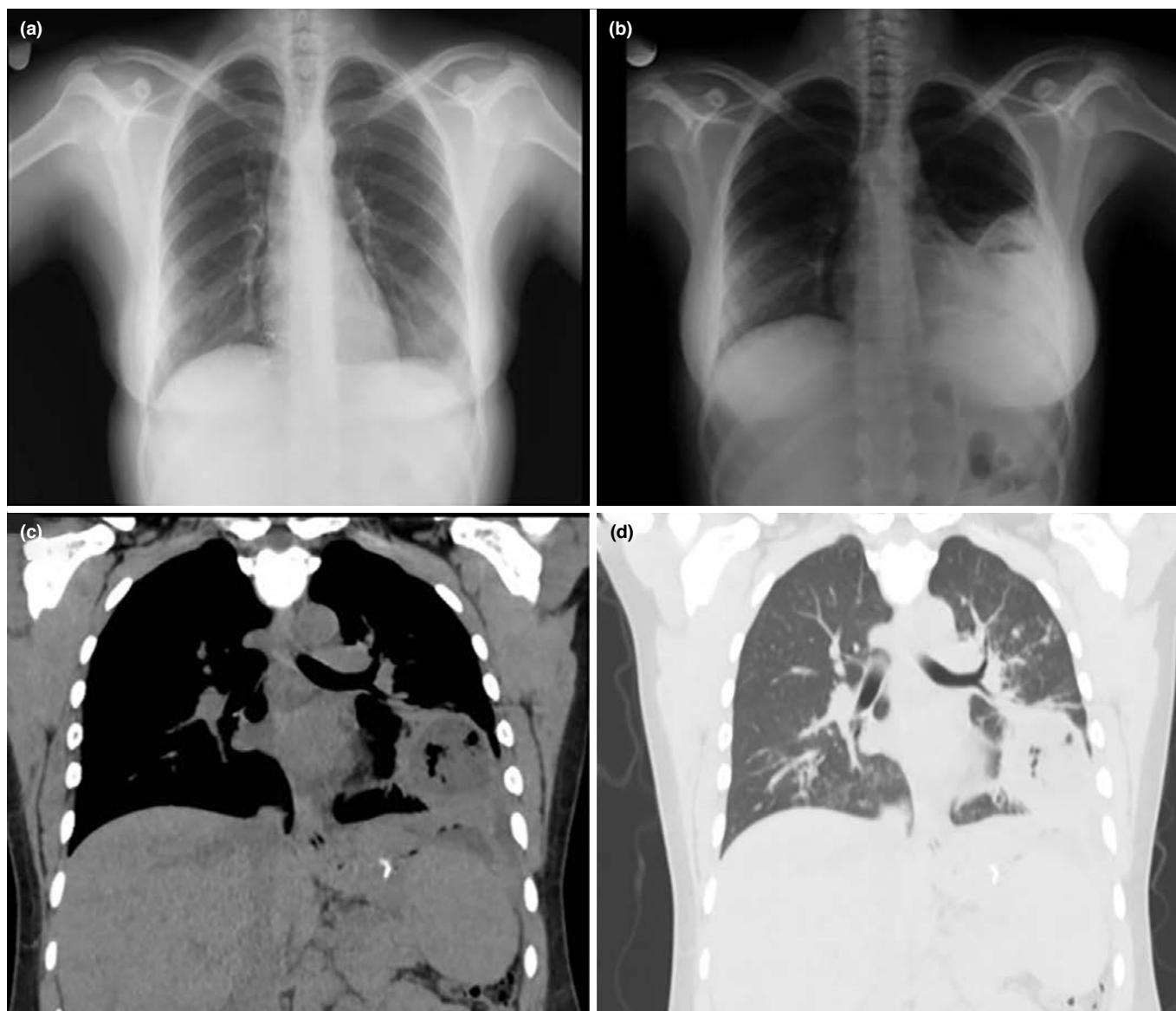


Figure 1: (a) A chest X-ray taken two months ago, which was completely normal before the breast prosthesis operation. (b) A chest X-ray demonstrating an air-fluid level-like density in the left lower zone. (c-d) A thoracic computed tomography (CT) revealing a 5 cm diameter cavitory mass lesion with thick walls and air-fluid densities in the left inferior lingular segment, along with associated consolidated areas

erode through the diaphragm, resulting in a pulmonary abscess that eventually drains into a bronchus.^[6]

A pulmonary abscess is an infectious pulmonary disease characterized by the presence of a pus-filled cavity within the lung parenchyma. Primary pulmonary abscesses occur in patients prone to aspiration or in otherwise healthy individuals, while secondary pulmonary abscesses typically develop in association with a stenosing lung neoplasm or a systemic disease that compromises immune defenses, such as acquired immunodeficiency syndrome (AIDS), or

following organ transplantation. The presence of a pulmonary abscess has been associated with high mortality, prolonged treatment duration, and significant costs.^[7]

In our patient, the postoperative period was unremarkable, so the gastro-bronchial fistula developed as a result of an insidious, persistent leak that may not have been large enough to generate symptoms. It is possible that the gastric contents, through this leak, may have extended into the left lower lung lobe, resulting in a gastro-bronchial fistula. In a French Multicentric Study, a retrospective study of

13 patients with gastro-bronchial fistula following sleeve gastrectomy, the mean duration before the appearance of symptoms was found to be 129 days (14–277 days).^[5] In a recent review, this duration was reported to range between 7 months and 30 months after surgery.^[8] To our knowledge, our patient had one of the longest durations before the appearance of symptoms published in English literature.

Due to the very rare incidence of gastro-bronchial fistula, evidence-based data regarding the gold standard diagnostic test are scarce. Our patient was initially managed for a pulmonary abscess refractory to medical treatment and subsequently underwent surgery via a left thoracotomy, where the diagnosis was definitively established. In our case, sleeve gastrectomy had been performed five years prior, and there were no symptoms suggestive of abdominal pathology. Detailed questioning regarding abdominal operations, particularly in cases of abscess located in the lower lobe of the lung and refractory to medical treatment, is essential. Regardless of the time elapsed since the operation, the possibility of gastro-bronchial fistula should not be overlooked during etiological investigations.

Informed Consent

Written informed consent was obtained from the patient for the publication of the case report and the accompanying images.

Authorship Contributions

Concept – M.S.A.; Design – O.K.; Supervision – N.Ç.Y.; Funding – M.S.A.; Materials – O.K.; Data collection &/ or processing – O.K.; Analysis and/ or interpretation – N.Ç.Y.; Literature search – M.S.A.; Writing – M.S.A.; Critical review – N.Ç.Y.

Conflicts of Interest

There are no conflicts of interest.

Use of AI for Writing Assistance

No AI technologies utilized.

Financial Support and Sponsorship

Nil.

Peer-review

Externally peer-reviewed.

References

1. Singhal R, Cardoso VR, Wiggins T, Super J, Ludwig C, Gkoutos GV, et al.; GENEVA Collaborators. 30-day morbidity and mortality of sleeve gastrectomy, Roux-en-Y gastric bypass and one anastomosis gastric bypass: a propensity score-matched analysis of the GENEVA data. *Int J Obes (Lond)* 2022;46(4):750–7. [\[CrossRef\]](#)
2. Goel R, Nasta AM, Goel M, Prasad A, Jammu G, Fobi M, et al. Complications after bariatric surgery: A multicentric study of 11,568 patients from Indian bariatric surgery outcomes reporting group. *J Minim Access Surg* 2021;17(2):213–20. [\[CrossRef\]](#)
3. Li M, Zeng N, Liu Y, Sun X, Yang W, Liu Y, et al.; Greater China Metabolic and Bariatric Surgery Database (GC-MBD) study group. Management and outcomes of gastric leak after sleeve gastrectomy: results from the 2010-2020 national registry. *Chin Med J (Engl)* 2023;136(16):1967–76. [\[CrossRef\]](#)
4. Saliba C, Nicolas G, Diab S, Joudi I, Tayar C. Gastrobronchial Fistula Following a Laparoscopic Sleeve Gastrectomy. *Am J Case Rep* 2019;20:31–5. [\[CrossRef\]](#)
5. Guillaud A, Moszkowicz D, Nedelcu M, Caballero-Caballero A, Rebibo L, Reche F, et al. Gastrobronchial Fistula: A Serious Complication of Sleeve Gastrectomy. Results of a French Multicentric Study. *Obes Surg* 2015;25(12):2352–9. [\[CrossRef\]](#)
6. Jha PK, Deiraniya AK, Keeling-Roberts CS, Das SR. Gastrobronchial fistula--a recent series. *Interact Cardiovasc Thorac Surg* 2003;2(1):6–8. [\[CrossRef\]](#)
7. Zhu T, Yang W, Lu W. Risk factors associated with length of hospital stay and medical expenses in pulmonary abscess patients: retrospective study. *PeerJ* 2023;11:e15106. [\[CrossRef\]](#)
8. Silva LB, Moon RC, Teixeira AF, Jawad MA, Ferraz AA, Neto MG, et al. Gastrobronchial Fistula in Sleeve Gastrectomy and Roux-en-Y Gastric Bypass--A Systematic Review. *Obes Surg* 2015;25(10):1959–65. [\[CrossRef\]](#)