

Access this article online

Quick Response Code:



Website:

<https://eurasianjpulmonol.org>

DOI:

10.14744/ejp.2024.5005

Immunotherapy-related pneumonitis

Merve Ayık Türk¹, Damla Serçe Unat², Nazan Erbaş Kanat³, Pınar Akın Kabalak⁴

ORCID:

Merve Ayık Türk: 0000-0003-3106-7403

Damla Serçe Unat: 0000-0003-4743-5469

Nazan Erbaş Kanat: 0000-0001-9269-0421

Pınar Akın Kabalak: 0000-0002-4087-7048

Abstract:

Immune checkpoint inhibitors (ICIs) are increasingly used in cancer treatment. Immune checkpoint inhibitor-related pneumonitis (ICI-P) is one of the immune-related adverse effects (irAE) and a leading cause of morbidity and mortality, defined as focal or diffuse inflammation of the lung parenchyma. Although ICI-P can occur in patients with malignancies, such as melanoma, renal cell cancer, and lymphoma, lung cancer patients are more susceptible to developing this condition. This rare side effect can be fatal. Dyspnea and cough are the most common symptoms. Organizing pneumonia is the most frequent radiological pattern; however, diffuse alveolar damage is more severe and life-threatening. Combined ICI blockade appears to improve clinical outcomes compared to monotherapy, but the incidence of pneumonitis increases with the combined use of agents. The mainstay of ICI-P treatment is corticosteroids; however, steroid-resistant cases may require alternative therapies. Early recognition and treatment are essential to prevent the progression of severe complications. This review analyzes the diagnosis and treatment strategies of ICI-P in detail.

Keywords:

Diagnosis, immunotherapy, pneumonitis, treatment

Introduction

Immune checkpoint inhibitors (ICIs), unlike conventional cytotoxic therapies, are treatments targeted tumor immune escape mechanisms that provide better survival advantages through both monotherapy and combination regimens.^[1,2] These drugs prevent tumor cells from evading the immune response by interacting with programmed cell death-1 protein 1 (PD-1), programmed death-ligand 1 (PD-L1), and cytotoxic T-lymphocyte-associated protein 4 (CTLA-4).

^[3] In general, T-helper 1 (Th1) CD4 and CD8

cells are the effector cells responsible for directing the antitumor immune responses of ICIs, controlled by multiple mechanisms. Through the T-cell receptor (TCR) and CD28, T cells are activated and produce cytokines, but inhibitory molecules that attenuate T-cell activation are also upregulated. Therefore, T cells have a limited window of activity before they are restrained to prevent damage to normal cells. The signals controlling antitumor immunity and immunosuppression form a tightly regulated process that maintains the balance of the immune response.^[4] If this balance is

Address for correspondence:

Dr. Merve Ayık Türk,
Department of
Pulmonology, İzmir
Bozyaka Training and
Research Hospital, İzmir,
Türkiye.
E-mail:
merve.ayik@hotmail.com

Received: 04-06-2024

Revised: 13-07-2024

Accepted: 17-07-2024

Published: 23-01-2025

How to cite this article: Ayık Türk M, Serçe Unat D, Erbaş Kanat N, Akın Kabalak P. Immunotherapy-related pneumonitis. Eurasian J Pulmonol 0000;00:1-10.

This is an open access journal, and articles are distributed under the terms of the Creative Commons Attribution-NonCommercial-ShareAlike 4.0 License, which allows others to remix, tweak, and build upon the work non-commercially, as long as appropriate credit is given and the new creations are licensed under the identical terms.

For reprints contact: kare@karepb.com

disturbed, the immune system may initiate a toxic process that affects multiple organs and systems.

Immune-related adverse events (irAEs) differ from the predictable side effects of conventional cancer therapies and can affect any organ, most commonly the skin, gastrointestinal tract, respiratory system, and endocrine system (including the thyroid, adrenal, and pituitary glands).^[5,6] Among these, immune checkpoint inhibitor-related pneumonitis (ICI-P) is defined as focal or diffuse inflammation of the lung parenchyma. Although the incidence varies based on tumor type and whether monotherapy or combination therapy is used, a meta-analysis reported the incidence of pneumonitis to be 2.14%.^[7] Although rare, it is the most common fatal adverse event among irAEs, with a mortality rate of up to 20%.^[8,9] Early diagnosis and treatment are critical to preventing severe outcomes.

Predisposing factors

The current oncological focus is on predicting which patients may or may not benefit from immunotherapy. Studies on programmed cell death protein 1 (PD-1)/programmed death-ligand 1 (PDL1) expression in tumor tissue or blood, various biomarkers, the tumor microenvironment, and tumor microbiota—recently gaining prominence—are frequently conducted. Another emerging issue of increasing importance is determining which patients are susceptible to developing immunotherapy-related side effects. Recently, publications have focused on identifying predisposing factors for ICI-P.^[10]

The first predisposing factor for the development of ICI-P is age. Studies have shown that patients younger than 65 years are more likely to experience severe toxicity and severe pneumonitis than older patients.^[11] However, there are publications with differing results regarding the relationship between gender and the risk of developing pneumonitis, and no definite consensus has been reached on this issue. On the other hand, due to the impaired immune balance caused by comorbidities such as high body mass index, metabolic syndrome, type 2 diabetes mellitus, coronary artery disease, and hyperlipidemia, it has been observed that individuals with these conditions have a higher risk of immunotherapy-related side effects. Specifically, in the case of pneumonitis, it was observed that patients with asthma, chronic obstructive pulmonary disease (COPD), interstitial pulmonary fibrosis (IPF)—particularly autoimmune-related interstitial fibrosis—and

those with a smoking history of more than 50 years are at increased risk of ICI-P. Therefore, immunotherapy candidates should be evaluated for conditions such as COPD and IPF through baseline radiography and pulmonary function tests. Similarly, patients with connective tissue diseases (characterized by blood autoantibody positivity or certain human leukocyte antigen [HLA] subtypes) have also been identified as being at higher risk for immunotherapy-related side effects.^[12,13] Cancer and autoimmune diseases are closely related, and many therapeutic antibodies are widely used in clinical settings to treat both conditions. Furthermore, immune checkpoint blockade using anti-PD1, anti-PD-L1, and anti-CTLA4 antibodies has improved the prognosis of patients with resistant solid tumors. However, excessive immune activation can also trigger autoimmune reactions. Therefore, treatment decisions for this special patient group should be made by a multidisciplinary team, with close follow-up.^[14]

Evidence from case studies and retrospective analyses has shown that the incidence of pneumonitis may be associated with a history of heavy antitumor treatments prior to immunotherapy, tumor histology, and former or current smoking status.^[15,16] Treatments such as chemotherapy and radiotherapy, administered before immunotherapy, may have pneumotoxic effects, and it is known that the risk of pneumonitis may increase when immunotherapy is used after these treatments. In patients for whom immunotherapy is planned, it is important to assess the treatment risks, particularly in those with a history of extensive antitumor therapy, and to administer immunotherapy under close monitoring to mitigate the possible risk of life-threatening pneumonitis.

When analyzing the relationship between cancer type and ICI-P, it is known that immunotherapy is used for various cancers, such as multiple myeloma, lung cancer, and renal cancer. The risk of ICI-P seems lower in patients with multiple myeloma and renal cell carcinoma in terms of side effect development. On the contrary, patients with breast cancer and non-small cell lung cancer (NSCLC) have been found to have a higher incidence of ICI-P, possibly due to the more frequent radiotherapy and concurrent chemotherapy in these patients.^[11] Among lung cancers, studies have shown a relationship between tumor histologic type and the incidence of ICI-P, with patients having non-squamous histology being at lower risk of developing ICI-P.^[17] Ad-

ditionally, the high incidence of concomitant chronic pulmonary diseases in smoking-related cancers may further increase the risk of ICI-P.

Recent studies have demonstrated a relationship between microbiota and ICI-P. A lower abundance of Bacteroides and a higher presence of Faecalibacterium or Firmicutes species in the intestinal flora have been associated with more immunotherapy-related side effects.^[12] In a previous study, immunotherapy-related side effects were observed more frequently in patients using antibiotics, suggesting that antibiotics should be used with caution in patients receiving immunotherapy.^[18]

Clinical findings

Patients with ICI-P typically present with symptoms similar to those of pneumonia. The first and most common complaint is shortness of breath. Since it can also be attributed to malignancy, patients may initially ignore this symptom. As the condition progresses, symptoms such as chest pain, cough, fever, and even hypoxia may develop.

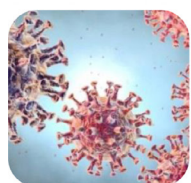
Although the most common clinical findings in ICI-P are dyspnea (80.3%) and cough (52.5%), fever (32.8%) and an asymptomatic state (6.6%) can also be observed, though rarely.^[19] The presence of new infiltrates on chest imaging, along with these symptoms in a patient receiving immunotherapy, supports the diagnosis of ICI-P.^[20] It has been shown that ICI-P typically begins within the first six months of immunotherapy, with high-grade pneumonitis occurring earlier than low-grade pneumonitis.^[17]

When pulmonary function test (PFT) findings in patients diagnosed with ICI-P are analyzed, reductions in Forced Vital Capacity (FVC), Vital Capacity (VC), and Carbon Monoxide Diffusion Capacity (DLCO) are observed. However, PFT volumes may be normal in patients with low-grade ICI-P, with DLCO being particularly sensitive.^[21]

Differential diagnosis

Due to the diversity of clinical presentations and radiological appearances, many etiological factors must be considered in the differential diagnosis [Fig. 1].

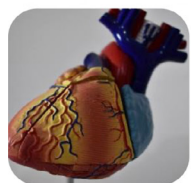Differential diagnosis



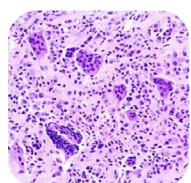
Infections: Since the clinical spectrum is wide and radiological findings are mostly ground-glass opacities or patchy nodular infiltrations^[22], pulmonary infections should be primarily ruled out in the differential diagnosis. Firstly, determination of the focus of infection, repeated blood and sputum cultures, sending nasopharyngeal swab samples and bronchoscopic cultures (if necessary) can be used in the differential diagnosis.



Tumor Progression: Lymphangitic spread is characterized by the spread of the tumor to the lymphatic vessels, peri lymphatic and peri bronchial connective tissue via lymphatics^[23]. Interventional procedures such as transbronchial biopsy or bronchoscopic BAL may be diagnostic in the differential diagnosis. Since lymphangitic invasion means progressive disease, it is important not to be late to decide anti-tumor treatment properly without delay.



Cardiovascular disease: Elderly patients with accompanying multiple comorbidities may provoke cardiac disease during the treatment process. Cardiotoxic effects of ICIs are also a well known irAE^[24]. Pulmonary findings that may be observed secondary to cardiac side effects including ground-glass opacities and interlobular septal thickenings observed in bilateral basals, which show similarities in the differential diagnosis with many diagnoses. B-type natriuretic peptide test and echocardiography are methods to guide clinicians.



Sarcoid-like granulomatous reactions: In addition to typical pneumonitis findings, hilar and mediastinal lymphadenopathies are other radiological findings^[25,26] and it may be challenging to confirm diagnosis. This finding can be confusing in a patient with malignancy by mimicking like tumour progression so additional diagnostic procedures such as endobronchial ultrasonography, serum angiotensin converting enzyme and serum calcium level may be needed in the differential diagnosis.

Figure 1: Differential diagnosis

Diagnosis and new diagnostic developments

Immune checkpoint inhibitor-related pneumonitis does not have any pathognomonic clinical or radiological findings for diagnosis. High-resolution computed tomography (HRCT), one of the most important diagnostic tools for ICI-P, should be performed when possible. The lower lobes are the most common sites of ICI-P involvement in the lungs, with the middle and upper lobes being less commonly affected.^[27] Radiological findings in ICI-P vary widely. The main imaging features include ground-glass opacity, consolidation, interlobular septal thickening, bronchial dilation, nodules, and reticular patterns. The types of lung damage observed on CT scans are broadly classified into four radiological appearances: organized pneumonia (OP), nonspecific interstitial pneumonia (NSIP), hypersensitivity pneumonitis (HP), and diffuse alveolar damage (DAD). The acute, severe form of DAD, which can result in severe respiratory failure, is known as acute respiratory distress syndrome (ARDS). When the pulmonary involvement of ICI-P is ranked in terms of severity, the pattern follows DAD>NSIP>HP>OP. While DAD/ARDS is the most severe form among these four groups, this involvement pattern, along with HP, is one of the rarest. The most common form is OP, with an incidence of 65%, followed by NSIP at 15%. Common computed tomography (CT) findings in OP include ground-glass opacities, consolidations, nodular lesions, and inverted halo signs. Ground-glass opacities are the most frequent radiological finding in ICI-P.^[28,29] Additionally, it has been observed that the presence of cryptogenic OP has been associated with increased immunotherapy efficacy.^[30]

Minimally invasive procedures, such as bronchial lavage fluid examinations or bronchial biopsy, may aid in the diagnosis, alongside radiology. Bronchoalveolar lavage (BAL) has long been used in the differential diagnosis of pneumonitis. Bronchoalveolar lavage examinations in patients with ICI-P typically reveal a differential cell count with a predominance of lymphocytes (usually over 20%). However, neutrophils or eosinophils above 10% may also be observed.^[31] Pathological evidence is heterogeneous, with most ICI-P samples obtained from transbronchial lung biopsy. Most reported cases involve lymphocytic infiltration, granulomatous inflammation, and organized pneumonia.

In addition to differential cell counts in BAL fluid, advanced investigations such as flow cytometry can also

be performed. Flow cytometry studies have shown that both CD4 (+) and CD8 (+) T cells constitute the majority of cells in BAL fluid and are involved in disease pathogenesis. T-helper 17 cells are predominant among T cells, and high expression of genes such as T-box transcription factor 21 (TBX21, encoding T-bet), retinoic acid receptor-related orphan receptor gamma (ROR- γ), interferon-gamma (IFN- γ), interleukin-17 alpha (IL-17 α), colony-stimulating factor 2 (CSF2, also known as granulocyte-macrophage colony-stimulating factor, GM-CSF), and cytotoxicity-related genes increases the risk of ICI-P development. With the increasing use of flow cytometry in clinical practice, it is believed that these proteins may serve as useful biomarkers for predicting the diagnosis and progression of ICI-P.^[32] Bronchoscopic biopsies typically show alveolitis characterized by organized pneumonia and alveolar septal thickening with lymphocyte predominance.^[33]

In recent years, the interpretation of radiological findings using new and advanced technologies such as machine learning, artificial intelligence, and radiomics has contributed to diagnostic procedures; however, these technologies are not yet widely used. Particularly in patients with lung cancer and suspected interstitial pneumonia, differentiating between cancer progression and interstitial pneumonia, as well as distinguishing viral or bacterial pneumonia in other diseases can be challenging for clinicians. As treatment options like immunotherapy and targeted therapies increase, leading to improved survival, cases in which radiotherapy and immunotherapy are used together are being encountered more frequently in routine practice.^[34,35] A study by Qui et al.^[36] revealed that a radiomics algorithm could be used to differentiate radiotherapy-related pneumonitis from ICI-P. In a review of radiomic analysis studies on ICI-P by Shu et al.,^[33] techniques using radiomic analysis, such as machine learning or deep learning, were found to be more effective than manual radiomic analysis. However, it was concluded that more radiomic-analyzed data sets are needed to achieve high accuracy in the differential diagnosis of this disease, which lacks a definitive diagnostic method.

Several biomarkers are frequently used in clinical practice to predict the risk of ICI-P development. Baseline low hemoglobin, low albumin, and a high neutrophil-to-lymphocyte ratio have been associated with ICI-P

Table 1: Grading of pneumonitis according to Common Terminology Criteria for Adverse Events (CTCAE v5.0)^[44]

Grade 1 (mild)	Asymptomatic with radiological findings
Grade 2 (moderate)	Symptomatic, limiting instrumental activities of daily living (ADL)
Grade 3 (severe)	Severe symptoms, limiting self-care ADL, requiring oxygen
Grade 4 (life-threatening)	Life-threatening respiratory compromise, requiring advanced oxygen delivery (e.g., mechanical ventilation)
Grade 5	Death related to pneumonitis

and other side effects. When cytokine levels were analyzed, interstitial organizing pneumonia was associated with low baseline levels of tumor necrosis factor alpha (TNF- α), IL-6, IL-8, interferon gamma-induced protein 10 (IP-10), CXCL9, CXCL10, CXCL11, and CXCL19, while a significant increase in IL-6, CXCL5, CXCL9, and CXCL10 levels was observed after treatment.^[12,37] Biomarkers with high accuracy are needed for ICI-P, as its clinical and radiological findings can be confused with other diseases. In this context, transforming growth factor beta 1 (TGF β 1), interleukins 1, 6, 8, and 10, Krebs von den Lungen-6 (KL-6), and surfactant proteins, which have been previously studied in interstitial changes, have been shown to be positive in ICI-P.^[10] In the future, the use of specific biomarkers to identify high-risk patient groups could help prevent irAEs. This would allow for early intervention or the implementation of closer patient follow-up protocols for those at higher risk.

Predicting risk according to immunotherapy agent

The risk of pneumonitis may vary depending on the immunotherapy agents used. In a meta-analysis, the incidence of severe pneumonitis was reported to be 3.2% with anti-PD1 and 2% with anti-PDL1.^[38] Another meta-analysis reported the incidence of pneumonitis to range from 0–10.6% for all grades with anti-PD1 agents and 0–4.3% for grade 3 and above, with no difference observed between the anti-PD1 agents nivolumab and pembrolizumab in terms of pneumonitis risk.^[39] The incidence of pneumonitis with anti-PDL1 agents, such as atezolizumab, was reported to be 2–3% for all grades,^[40–42] while the rate of pneumonitis with anti-CTLA4 monotherapy was less than 1%.^[25] Although the incidences of pneumonitis are similar between anti-PD1 and anti-PDL1 monotherapies, studies have shown relatively low rates of pneumonitis with anti-CTLA4 monotherapy.^[9,43] Combined ICI blockade appears to improve clinical outcomes compared to monotherapy.^[44] though the incidence of pneumonitis varies with the combined use of agents.^[7] When anti-PD1 monotherapy was compared with

combination therapies, the incidence of pneumonitis across all grades was found to be significantly higher in the combination group (2.7% vs. 6.6%).^[39] Among patients receiving anti-PD1 and anti-PDL1 monotherapy, the incidence of pneumonitis was higher in the combination arm compared to those receiving anti-CTLA4 combination therapy.^[19] In a study evaluating pneumonitis with ICI and combination therapies, it was found that the combination of anti-PD1 + chemotherapy (1.76, 95% confidence interval [CI] 1.52–2.05) and anti-CTLA4 + chemotherapy (2.36, 95% CI 1.67–3.35) was associated with pneumonitis, whereas no association was found between the combination of anti-PDL1+ chemotherapy and the incidence of pneumonitis.^[45] In another meta-analysis, contrary to previous results, the combination of anti-PD1 + chemotherapy and anti-PDL1+ chemotherapy was found to have a lower incidence of pneumonitis compared to monotherapy (2.2% vs. 2.48%; 2% vs. 2.48%, respectively). The incidence of pneumonitis with the anti-CTLA4 combination was reported to be 3.43% in the same study. In this meta-analysis, the decrease in incidence with combined regimens was attributed to the protective immune inhibition effect of concomitant cytotoxic drugs or corticosteroids (used as pretreatment agents) against ICIs.^[38] When evaluating the broader literature, combined ICI treatments tend to increase the risk of pneumonitis compared to monotherapies. Early identification of the risk of pneumonitis with combination therapies and implementing protective measures early may reduce the risk of ICI-P.

Treatment approaches and grading in ICI-Ps

After the diagnosis of pneumonitis in lung cancer patients receiving immunotherapy, these patients should be evaluated using the Common Terminology Criteria for Adverse Events (CTCAE) severity scale, and the severity of pneumonitis should be graded and managed accordingly. According to this scale, ICI-P is classified from grade 1, which is asymptomatic, to grade 5, which results in death (Table 1).^[46]

Table 2: Treatment recommendations from European Society for Medical Oncology (ESMO) guidelines according to the grading of Common Terminology Criteria for Adverse Events (CTCAE)

Grade 1 Asymptomatic	Baseline indications: <ul style="list-style-type: none"> • Computed tomography with contrast – repeat as necessary • Pulse oximetry • Laboratory tests • Respiratory function test • Sputum sample (screening for viral opportunistic panel, opportunistic pathogens, or specific bacterial infections) 	Monitoring: <ul style="list-style-type: none"> • Symptom monitoring every 2–3 days • In case of symptom worsening, manage as in Grade ≥ 2
Grade 2 Symptomatic with limitation of instrumental activities	Outpatient monitoring: <ul style="list-style-type: none"> • Daily symptom monitoring • Computed tomography (CT) of the thorax with contrast • Sputum, blood, and urine cultures • Bronchoscopy with Bronchoalveolar Lavage (BAL) • Weekly thoracic X-ray and pulmonary function test (PFT) monitoring, including transfer factor for carbon monoxide (TLCO) 	Treatment: <ul style="list-style-type: none"> • Withhold immunotherapy • Start empirical antibiotics if infection is suspected • If no evidence of infection or no response to antibiotics after 48 hours, initiate oral prednisolone at 1 mg/kg/day • If no response within 48 hours, treat as \geqGrade 3
Grade 3–4 Severe new symptoms, life-threatening, acute respiratory distress syndrome (ARDS)	Hospitalization: <ul style="list-style-type: none"> • In addition to baseline diagnostic assessment: • High-resolution computed tomography (HRCT) • Bronchoscopy with BAL\pmtransbronchial biopsy 	Treatment: <ul style="list-style-type: none"> • Discontinue immunotherapy • Administer 2–4 mg/kg/day intravenous (i.v.) methylprednisolone • Review empirical antibiotic treatment, escalate as needed, and initiate ventilation if necessary

If no response within 48–72 hours, consider alternative treatment options and assess for differential diagnoses.

In line with the recommendations of the European Society of Medical Oncology (ESMO), immunotherapy can be continued when grade 1 pneumonitis is diagnosed, but close follow-up with symptom monitoring every 2–3 days and repeat imaging at least every 3 weeks is recommended. In cases of grade 2 pneumonitis, immunotherapy should be interrupted, empirical antibiotic treatment should be initiated if infection is suspected, and 1 mg/kg/day of oral prednisolone or an equivalent corticosteroid (CS) should be administered. If there is no response within 48–72 hours to CS treatment, management should follow protocols for grade 3 or 4 pneumonitis. For patients with grade 3 or higher pneumonitis, parenteral administration of 2–4 mg/kg/day of methylprednisolone or an equivalent CS should be initiated after hospitalization. Empirical antibiotic treatment should be reassessed, and the spectrum should be escalated if necessary. In cases where oxygen therapy is insufficient, non-invasive or invasive mechanical ventilation should be provided without delay (Table 2).^[47] In patients who do not respond to these therapies, other immunosuppressive or immunomodulatory treatment options should be considered.

After complete symptomatic improvement, the steroid dose should be tapered over 4–6 weeks for grade 2 pneumonitis and ≥ 6 –8 weeks for grade 3 pneumonitis. If the toxic event resolves without complications, resumption of immunotherapy may be considered for patients with grade 2 or lower, with close clinical follow-up. However, the resumption of immunotherapy should be postponed until the daily steroid dose is ≤ 10 mg of prednisolone. According to the literature, it has been reported that the risk of relapse increases when the first episode of pneumonitis occurs early (< 12 weeks) and the duration of steroid treatment is shorter than 5 weeks. Recurrent cases usually have a more severe course than the first episode.^[48,49]

Treatment approach in steroid-resistant cases

The mainstay of treatment is corticosteroids; however, steroid-resistant cases present a challenge for clinicians in clinical practice. The optimal time to discontinue steroids, switch to alternative treatments, determine the appropriate dose, and establish the duration of treatment remains unclear.^[50] In grade 3 and above pneumonitis, intravenous immunoglobulin (IVIG) and other immunosuppressive treatments should be considered

if there is no response to steroids within 48–72 hours.^[28,43,51–55] Intravenous immunoglobulin exerts an immunomodulatory effect through three mechanisms: 1) regulating the function of immune cells causing inflammation, 2) binding and neutralizing autoantibodies, and 3) downregulating the expression of various chemokines and cytokines.^[56] Although biological agents such as tumor necrosis factor inhibitors have been associated with increased risks of malignancy and infection, the literature reports that adding these agents to the treatment of steroid-resistant pneumonitis provides clinical im-

provement.^[52,53] Tocilizumab, an interleukin-6 inhibitor, has also been reported as a potential therapeutic option for steroid-resistant pneumotoxicity.^[51]

Other immunosuppressant treatment options suppress the proliferation of immune cells through different mechanisms and act by inhibiting the antibody-mediated immune response. The following table lists various alternative treatment strategies and drugs currently under investigation, which may provide future alternatives for the treatment of ICI-P (Table 3).

Table 3: Alternative treatment regimens

IVIg ^[54]	<ul style="list-style-type: none"> Regulates the function of immune cells that cause inflammation, Binds and neutralizes autoantibodies, Downregulates the expression of various chemokines and cytokines 	2 g/kg IVIG, 2–5 per day
Mycophenolate mofetil ^[55] and Cyclophosphamide ^[43]	<ul style="list-style-type: none"> Inhibit immune cell proliferation and function Suppress the antibody response 	1g, 2x1 iv
Infliximab ^[49,52,53]	<ul style="list-style-type: none"> TNF-α inhibitor 	5 mg/kg, single dose, repeat every 2 weeks if necessary
Tocilizumab ^[51]	<ul style="list-style-type: none"> IL-6 inhibitor 	8 mg/kg, single dose, repeat every 2 weeks if necessary
Secukinumab ^[55]	<ul style="list-style-type: none"> IL-17 inhibitor 	Effective in immunotherapy-associated psoriasiform dermatological toxicity (case reports)
Ustekinumab ^[57,58]	<ul style="list-style-type: none"> IL-12 inhibitor 	Effective in the treatment of immunotherapy-associated colitis
Guselkumab ^[57,58]	<ul style="list-style-type: none"> IL-23 inhibitor 	Effective in immunotherapy-associated psoriasiform dermatological toxicity
Canakinumab ^[59]	<ul style="list-style-type: none"> IL-1 inhibitor 	Effective in treating various autoimmune inflammations, with high potential in treating pneumonitis
Mepolizumab ^[60]	<ul style="list-style-type: none"> IL-5 inhibitor 	High potential in treating ICI-P by suppressing serum eosinophil count
Tralokinumab ^[61]	<ul style="list-style-type: none"> IL-13 inhibitor 	Approved for atopic dermatitis, potential for severe ICI-P treatment
Eculizumab, Ravulizumab ^[62]	<ul style="list-style-type: none"> C3a inhibitor 	Approved for paroxysmal nocturnal hemoglobinuria, with potential for severe ICI-P treatment
Sargramostim ^[63]	<ul style="list-style-type: none"> GM-CSF 	Found effective in reducing ICI-P and improving survival (Phase 2 studies)
Vedolizumab ^[64]	<ul style="list-style-type: none"> α 4 integrin inhibitor 	Approved for IBD, has a good safety profile with long-term use, potential for severe IBD treatment
Ruxolitinib, Baricitinib, Tofacitinib, Upadacitinib ^[65,66]	<ul style="list-style-type: none"> JAK-related pathway inhibitors 	
Oclacitinib (NCT05305066 under investigation in clinical trials)		
Evobrutinib ^[67] (NCT03934502 under investigation in clinical trials)	<ul style="list-style-type: none"> BTK-related pathway inhibitor 	
Tirabrutinib (NCT02626026 under investigation in clinical trials)		
Tomivosertib ^[68]	<ul style="list-style-type: none"> MNK1/2-related pathway inhibitor 	
Sirolimus ^[69]	<ul style="list-style-type: none"> mTOR-related pathway inhibitor 	Studies have shown that sirolimus not only relieves colitis by reducing T-cell infiltration but also inhibits tumor growth.

IVIg: Intravenous Immunoglobulin, iv: Intravenous, TNF: Tumor necrosis factor, IL: Interleukin, ICI-P: Immune checkpoint inhibitor-related pneumonitis, GM-CSF: Granulocyte-macrophage colony-stimulating factor, IBD: Inflammatory bowel diseases, JAK: Janus kinase, BTK: Bruton tyrosine kinase inhibitor, MNK: Mitogen-activated protein kinase-interacting kinase inhibitor, mTOR: Mammalian target of rapamycin

In conclusion, it is clear that clinicians need evidence-based guidance with more precise recommendations regarding pulmonary toxicity. The optimal management of immunotherapy-associated pulmonary toxicity remains an open question that needs to be addressed, especially when considering the current state and future direction of cancer treatment.

Re-challenge with immunotherapy

As expected, the adverse effects of ICIs are rarely fatal and usually improve with discontinuation of treatment or the administration of corticosteroids. Guidelines recommend stopping immunotherapy in case of life-threatening (grade 4) and serious (grade 3) adverse events.^[70,71] The decision to restart ICIs after irAEs is complex and should be discussed with a multidisciplinary team, considering individualized factors such as the patient's cancer status, response to immunotherapy, availability of alternative effective treatments, and resolution of observed toxicities. In a study involving lung cancer patients, re-irAEs were observed in 20% of patients who restarted ICIs after ICI-P. Recurrence was associated with having experienced grade ≥ 3 ICI-P during the first pneumonitis episode, an Eastern Cooperative Oncology Group (ECOG) performance status of ≥ 2 , and elevated levels of IL-6, C-reactive protein, white blood cell count, and neutrophil count at the time of re-administration.^[72] If re-administration of immunotherapy is deemed necessary, it should be restarted under close monitoring due to the risks of monotherapy with a different drug and the potential for recurrent and/or subsequent irAEs.

Authorship Contributions

Concept – P.A.K.; Design – P.A.K.; Supervision – P.A.K.; Funding – M.A.T., D.S.U., N.E.K., P.A.K.; Materials – M.A.T., D.S.U., N.E.K.; Data collection &/or processing – M.A.T., D.S.U., N.E.K.; Analysis and/or interpretation – M.A.T., D.S.U., N.E.K.; Literature search – M.A.T., D.S.U., N.E.K.; Writing – M.A.T., D.S.U., N.E.K.; Critical review – P.A.K.

Conflicts of Interest

There are no conflicts of interest.

Use of AI for Writing Assistance

No AI technologies utilized.

Financial Support and Sponsorship

Nil.

Peer-review

Externally peer-reviewed.

References

- Herbst RS, Baas P, Kim DW, Felip E, Pérez-Gracia JL, Han JY, et al. Pembrolizumab versus docetaxel for previously treated, PD-L1-positive, advanced non-small-cell lung cancer (KEYNOTE-010): a randomised controlled trial. *Lancet* 2016;387(10027):1540–50.
- Antonia SJ, Villegas A, Daniel D, Vicente D, Murakami S, Hui R, et al.; PACIFIC Investigators. Durvalumab after Chemoradiotherapy in Stage III Non-Small-Cell Lung Cancer. *N Engl J Med* 2017;377(20):1919–29.
- Dafni U, Tsourti Z, Vervita K, Peters S. Immune checkpoint inhibitors, alone or in combination with chemotherapy, as first-line treatment for advanced non-small cell lung cancer. A systematic review and network meta-analysis. *Lung Cancer* 2019;134:127–40.
- Sharma P, Siddiqui BA, Anandhan S, Yadav SS, Subudhi SK, Gao J, et al. The Next Decade of Immune Checkpoint Therapy. *Cancer Discov* 2021;11(4):838–57.
- Szuchan C, Elson L, Alley E, Leung K, Camargo AL, Elimimian E, et al. Checkpoint inhibitor-induced myocarditis and myasthenia gravis in a recurrent/metastatic thymic carcinoma patient: a case report. *Eur Heart J Case Rep* 2020;4(3):1–8.
- Brahmer JR, Lacchetti C, Schneider BJ, Atkins MB, Brassil KJ, Caterino JM, et al.; National Comprehensive Cancer Network. Management of Immune-Related Adverse Events in Patients Treated With Immune Checkpoint Inhibitor Therapy: American Society of Clinical Oncology Clinical Practice Guideline. *J Clin Oncol* 2018;36(17):1714–68.
- Liu H, Luo SX, Jie J, Peng L, Wang S, Song L. Immune checkpoint inhibitors related respiratory disorders in patients with lung cancer: A meta-analysis of randomized controlled trials. *Front Immunol* 2023;14:1115305.
- Suresh K, Psoter KJ, Voong KR, Shankar B, Forde PM, Ettinger DS, et al. Impact of Checkpoint Inhibitor Pneumonitis on Survival in NSCLC Patients Receiving Immune Checkpoint Immunotherapy. *J Thorac Oncol* 2019;14(3):494–502.
- Wang DY, Salem JE, Cohen JV, Chandra S, Menzer C, Ye F, et al. Fatal Toxic Effects Associated With Immune Checkpoint Inhibitors: A Systematic Review and Meta-analysis. *JAMA Oncol* 2018;4(12):1721–8. Erratum in: *JAMA Oncol* 2018;4(12):1792.
- Guberina N, Wirsdörfer F, Stuschke M, Jendrossek V. Combined radiation- and immune checkpoint-inhibitor-induced pneumonitis - The challenge to predict and detect overlapping immune-related adverse effects from evolving laboratory biomarkers and clinical imaging. *Neoplasia* 2023;39:100892.
- Kalinich M, Murphy W, Wongvibulsin S, Pahalyants V, Yu KH, Lu C, et al. Prediction of severe immune-related adverse events requiring hospital admission in patients on immune checkpoint inhibitors: study of a population level insurance claims database from the USA. *J Immunother Cancer* 2021;9(3):e001935.
- Chennamadhavuni A, Abushahin L, Jin N, Presley CJ, Manne A. Risk Factors and Biomarkers for Immune-Related Adverse Events: A Practical Guide to Identifying High-Risk Patients and Rechallenging Immune Checkpoint Inhibitors. *Front Immunol* 2022;13:779691.
- Zeng Y, Shi Q, Liu X, Tang H, Lu B, Zhou Q, et al. Dynamic gut microbiota changes in patients with advanced malignancies experiencing secondary resistance to immune checkpoint inhibitors and immune-related adverse events. *Front Oncol* 2023;13:1144534.

14. Yasunaga M. Antibody therapeutics and immunoregulation in cancer and autoimmune disease. *Semin Cancer Biol* 2020;64:1–12.
15. Koyama N, Iwase O, Nakashima E, Kishida K, Kondo T, Watanabe Y, et al. High incidence and early onset of nivolumab-induced pneumonitis: four case reports and literature review. *BMC Pulm Med* 2018;18(1):23.
16. Naidoo J, Nishino M, Patel SP, Shankar B, Rekhman N, Illei P, et al. Immune-Related Pneumonitis After Chemoradiotherapy and Subsequent Immune Checkpoint Blockade in Unresectable Stage III Non-Small-Cell Lung Cancer. *Clin Lung Cancer* 2020;21(5):e435–4.
17. Suresh K, Voong KR, Shankar B, Forde PM, Ettinger DS, Marrone KA, Kelly RJ, Hann CL, Levy B, Feliciano JL, Brahmer JR, Feller-Kopman D, Lerner AD, Lee H, Yarmus L, D'Alessio F, Hales RK, Lin CT, Psoter KJ, Danoff SK, Naidoo J. Pneumonitis in Non-Small Cell Lung Cancer Patients Receiving Immune Checkpoint Immunotherapy: Incidence and Risk Factors. *J Thorac Oncol*. 2018 Dec;13(12):1930-1939. doi: 10.1016/j.jtho.2018.08.2035. Epub 2018 Sep 26. PMID: 30267842.
18. Jing Y, Chen X, Li K, Liu Y, Zhang Z, Chen Y, Liu Y, Wang Y, Lin SH, Diao L, Wang J, Lou Y, Johnson DB, Chen X, Liu H, Han L. Association of antibiotic treatment with immune-related adverse events in patients with cancer receiving immunotherapy. *J Immunother Cancer*. 2022 Jan;10(1):e003779. doi: 10.1136/jitc-2021-003779. PMID: 35058327; PMCID: PMC8772460.
19. Delaunay M, Cadranet J, Lusque A, Meyer N, Gounant V, Moro-Sibilot D, Michot JM, Raimbourg J, Girard N, Guisier F, Planchard D, Metivier AC, Tomasini P, Dansin E, Pérol M, Campana M, Gautschi O, Früh M, Fumet JD, Audigier-Valette C, Couraud S, Dalle S, Leccia MT, Jaffro M, Collot S, Prévot G, Milia J, Mazieres J. Immune-checkpoint inhibitors associated with interstitial lung disease in cancer patients. *Eur Respir J*. 2017 Aug 10;50(2):1700050. doi: 10.1183/13993003.00050-2017. Erratum in: *Eur Respir J*. 2017 Nov 9;50(5):1750050. doi: 10.1183/13993003.50050-2017. PMID: 28798088.
20. Hao Y, Zhang X, Yu L. Immune checkpoint inhibitor-related pneumonitis in non-small cell lung cancer: A review. *Front Oncol* 2022;12:911906.
21. Cadranet J, Canellas A, Matton L, Darrason M, Parrot A, Naccache JM, et al. Pulmonary complications of immune checkpoint inhibitors in patients with nonsmall cell lung cancer. *Eur Respir Rev* 2019;28(153):190058.
22. O'Kane GM, Labbé C, Doherty MK, Young K, Albaba H, Leighl NB. Monitoring and Management of Immune-Related Adverse Events Associated With Programmed Cell Death Protein-1 Axis Inhibitors in Lung Cancer. *Oncologist* 2017;22(1):70–80.
23. Bruce DM, Heys SD, Eremin O. Lymphangitis carcinomatosa: a literature review. *J R Coll Surg Edinb* 1996;41(1):7–13.
24. Rubio-Infante N, Ramirez-Flores YA, Castillo EC, Lozano O, García-Rivas G, Torre-Amione G. Cardiotoxicity associated with immune checkpoint inhibitor therapy: a meta-analysis. *Eur J Heart Fail* 2021;23(10):1739–47.
25. Chuzi S, Tavora F, Cruz M, Costa R, Chae YK, Carneiro BA, et al. Clinical features, diagnostic challenges, and management strategies in checkpoint inhibitor-related pneumonitis. *Cancer Manag Res* 2017;9:207–13.
26. Reuss JE, Kunk PR, Stowman AM, Gru AA, Slingluff CL Jr, Gaughan EM. Sarcoidosis in the setting of combination ipilimumab and nivolumab immunotherapy: a case report & review of the literature. *J Immunother Cancer* 2016;4:94.
27. Hu Q, Wang S, Ma L, Sun Z, Liu Z, Deng S, et al. Radiological assessment of immunotherapy effects and immune checkpoint-related pneumonitis for lung cancer. *J Cell Mol Med* 2024;28(5):e17895.
28. Nishino M, Ramaiya NH, Awad MM, Sholl LM, Maattala JA, Taibi M, et al. PD-1 Inhibitor-Related Pneumonitis in Advanced Cancer Patients: Radiographic Patterns and Clinical Course. *Clin Cancer Res* 2016;22(24):6051–60.
29. Lin X, Deng H, Chen L, Wu D, Chen X, Yang Y, et al. Clinical types of checkpoint inhibitor-related pneumonitis in lung cancer patients: a multicenter experience. *Transl Lung Cancer Res* 2021;10(1):415–29.
30. Cho JY, Kim J, Lee JS, Kim YJ, Kim SH, Lee YJ, et al. Characteristics, incidence, and risk factors of immune checkpoint inhibitor-related pneumonitis in patients with non-small cell lung cancer. *Lung Cancer* 2018;125:150–6.
31. Nishiyama O, Shimizu S, Haratani K, Isomoto K, Tanizaki J, Hayashi H, et al. Clinical implications of bronchoscopy for immune checkpoint inhibitor-related pneumonitis in patients with non-small cell lung cancer. *BMC Pulm Med* 2021;21(1):155.
32. Franken A, Van Mol P, Vanmassenhove S, Donders E, Schepers R, Van Brussel T, et al. Single-cell transcriptomics identifies pathogenic T-helper 17.1 cells and pro-inflammatory monocytes in immune checkpoint inhibitor-related pneumonitis. *J Immunother Cancer* 2022;10(9):e005323.
33. Shu Y, Xu W, Su R, Ran P, Liu L, Zhang Z, et al. Clinical applications of radiomics in non-small cell lung cancer patients with immune checkpoint inhibitor-related pneumonitis. *Front Immunol* 2023;14:1251645.
34. Wen Q, Yang Z, Dai H, Feng A, Li Q. Radiomics Study for Predicting the Expression of PD-L1 and Tumor Mutation Burden in Non-Small Cell Lung Cancer Based on CT Images and Clinicopathological Features. *Front Oncol* 2021;11:620246.
35. Ettinger DS, Wood DE, Aisner DL, Akerley W, Bauman JR, Bharat A, et al. NCCN Guidelines Insights: Non-Small Cell Lung Cancer, Version 2.2021. *J Natl Compr Canc Netw* 2021;19(3):254–66.
36. Qiu Q, Xing L, Wang Y, Feng A, Wen Q. Development and Validation of a Radiomics Nomogram Using Computed Tomography for Differentiating Immune Checkpoint Inhibitor-Related Pneumonitis From Radiation Pneumonitis for Patients With Non-Small Cell Lung Cancer. *Front Immunol* 2022;13:870842.
37. Oyanagi J, Koh Y, Sato K, Mori K, Teraoka S, Akamatsu H, et al. Predictive value of serum protein levels in patients with advanced non-small cell lung cancer treated with nivolumab. *Lung Cancer* 2019;132:107–113.
38. Zhou C, Li M, Wang Z, An D, Li B. Adverse events of immunotherapy in non-small cell lung cancer: A systematic review and network meta-analysis. *Int Immunopharmacol* 2022;102:108353.
39. Nishino M, Giobbie-Hurder A, Hatabu H, Ramaiya NH, Hodi FS. Incidence of Programmed Cell Death 1 Inhibitor-Related Pneumonitis in Patients With Advanced Cancer: A Systematic Review and Meta-analysis. *JAMA Oncol* 2016;2(12):1607–16.
40. Fehrenbacher L, Spira A, Ballinger M, Kowanzet M, Vansteenkiste J, Mazieres J, et al.; POPLAR Study Group. Atezolizumab versus docetaxel for patients with previously treated non-small-cell lung cancer (POPLAR): a multicentre, open-label, phase 2 randomised controlled trial. *Lancet* 2016;387(10030):1837–46.
41. McDermott DF, Sosman JA, Sznol M, Massard C, Gordon MS, Hamid O, et al. Atezolizumab, an Anti-Programmed Death-Ligand 1 Antibody, in Metastatic Renal Cell Carcinoma: Long-Term Safety, Clinical Activity, and Immune Correlates From a Phase Ia Study. *J Clin Oncol* 2016;34(8):833–42.

42. Rosenberg JE, Hoffman-Censits J, Powles T, van der Heijden MS, Balar AV, Necchi A, et al. Atezolizumab in patients with locally advanced and metastatic urothelial carcinoma who have progressed following treatment with platinum-based chemotherapy: a single-arm, multicentre, phase 2 trial. *Lancet* 2016;387(10031):1909–20.
43. Naidoo J, Wang X, Woo KM, Iyriboz T, Halpenny D, Cunningham J, et al. Pneumonitis in Patients Treated With Anti-Programmed Death-1/Programmed Death Ligand 1 Therapy. *J Clin Oncol* 2017;35(7):709–17. Erratum in: *J Clin Oncol* 2017;35(22):2590.
44. Antonia SJ, López-Martin JA, Bendell J, Ott PA, Taylor M, Eder JP, et al. Nivolumab alone and nivolumab plus ipilimumab in recurrent small-cell lung cancer (CheckMate 032): a multicentre, open-label, phase 1/2 trial. *Lancet Oncol* 2016;17(7):883–95. Erratum in: *Lancet Oncol* 2016;17(7):e270. Erratum in: *Lancet Oncol* 2019;20(2):e70.
45. Li H, Zheng Y, Xu P, Li Z, Kuang Y, Feng X, et al. Comparison of pneumonitis risk between immunotherapy alone and in combination with chemotherapy: an observational, retrospective pharmacovigilance study. *Front Pharmacol* 2023;14:1142016.
46. National Cancer Institute Common terminology criteria for adverse events (CTCAE). Available at: https://ctep.cancer.gov/protocoldevelopment/electronic_applications/ctc.htm. Accessed Oct 15, 2021.
47. Haanen J, Obeid M, Spain L, Carbone F, Wang Y, Robert C, et al.; ESMO Guidelines Committee. Electronic address: clinicalguidelines@esmo.org. Management of toxicities from immunotherapy: ESMO Clinical Practice Guideline for diagnosis, treatment and follow-up. *Ann Oncol* 2022;33(12):1217–38.
48. Asher N, Marom EM, Ben-Betzalel G, Baruch EN, Steinberg-Silman Y, Schachter J, et al. Recurrent Pneumonitis in Patients with Melanoma Treated with Immune Checkpoint Inhibitors. *Oncologist* 2019;24(5):640–7.
49. de Jong C, Peters BJM, Schramel FMNH. Recurrent Episodes of Nivolumab-Induced Pneumonitis after Nivolumab Discontinuation and the Time Course of Carcinoembryonic Antigen Levels: A Case of a 58-Year-Old Woman with Non-Small Cell Lung Cancer. *Chemotherapy* 2018;63(5):272–7.
50. Sears CR, Peikert T, Possick JD, Naidoo J, Nishino M, Patel SP, et al. Knowledge Gaps and Research Priorities in Immune Checkpoint Inhibitor-related Pneumonitis. An Official American Thoracic Society Research Statement. *Am J Respir Crit Care Med* 2019;200(6):e31–43.
51. Stroud CR, Hegde A, Cherry C, Naqash AR, Sharma N, Addepalli S, et al. Tocilizumab for the management of immune mediated adverse events secondary to PD-1 blockade. *J Oncol Pharm Pract* 2019;25(3):551–7.
52. Cooksley T, Marshall W, Gupta A. Early infliximab in life-threatening immune-mediated pneumonitis. *QJM* 2019;112(12):929–30.
53. Sawai Y, Katsuya Y, Shinozaki-Ushiku A, Iwasaki A, Fukayama M, Watanabe K, et al. Rapid temporal improvement of pembrolizumab-induced pneumonitis using the anti-TNF- α antibody infliximab. *Drug Discov Ther* 2019;13(3):164–7.
54. Petri CR, Patell R, Batalini F, Rangachari D, Hallowell RW. Severe pulmonary toxicity from immune checkpoint inhibitor treated successfully with intravenous immunoglobulin: Case report and review of the literature. *Respir Med Case Rep* 2019;27:100834.
55. Johnson D, Patel AB, Uemura MI, Trinh VA, Jackson N, Zobniw CM, et al. IL17A Blockade Successfully Treated Psoriasiform Dermatologic Toxicity from Immunotherapy. *Cancer Immunol Res* 2019;7(6):860–65.
56. Hallowell RW, Amariei D, Danoff SK. Intravenous immunoglobulin as potential adjunct therapy for interstitial lung disease. *Ann Am Thorac Soc* 2016;13:1682–8.
57. Phillips GS, Wu J, Hellmann MD, Postow MA, Rizvi NA, Freites-Martinez A, et al. Treatment Outcomes of Immune-Related Cutaneous Adverse Events. *J Clin Oncol* 2019;37(30):2746–58.
58. Thomas AS, Ma W, Wang Y. Ustekinumab for Refractory Colitis Associated with Immune Checkpoint Inhibitors. *N Engl J Med* 2021;384(6):581–3.
59. Dinarello CA, Simon A, van der Meer JW. Treating inflammation by blocking interleukin-1 in a broad spectrum of diseases. *Nat Rev Drug Discov* 2012;11(8):633–52.
60. Wechsler ME, Akuthota P, Jayne D, Houry P, Klion A, Langford CA, et al.; EGPA Mepolizumab Study Team. Mepolizumab or Placebo for Eosinophilic Granulomatosis with Polyangiitis. *N Engl J Med* 2017;376(20):1921–32.
61. Duggan S. Tralokinumab: First Approval. *Drugs* 2021;81(14):1657–63. Erratum in: *Drugs* 2021;81(15):1811. Erratum in: *Drugs* 2021;81(15):1813.
62. Frieri C, Peffault de Latour R, Sicre De Fontbrune F. Emerging drugs for the treatment of paroxysmal nocturnal hemoglobinuria. *Expert Opin Emerg Drugs* 2022;27(1):33–43.
62. Hodi FS, Lee S, McDermott DF, Rao UN, Butterfield LH, Tarhini AA, et al. Ipilimumab plus sargramostim vs ipilimumab alone for treatment of metastatic melanoma: a randomized clinical trial. *JAMA* 2014;312(17):1744–53.
63. Loftus EV Jr, Feagan BG, Panaccione R, Colombel JF, Sandborn WJ, Sands BE, et al. Long-term safety of vedolizumab for inflammatory bowel disease. *Aliment Pharmacol Ther* 2020;52(8):1353–65.
65. Bishu S, Melia J, Sharfman W, Lao CD, Fecher LA, Higgins PDR. Efficacy and Outcome of Tofacitinib in Immune checkpoint Inhibitor Colitis. *Gastroenterology*. 2021;160(3):932–934.e3.
66. Goyal P, Choi JJ, Pinheiro LC, Schenck EJ, Chen R, Jabri A, et al. Clinical Characteristics of Covid-19 in New York City. *N Engl J Med* 2020;382(24):2372–4.
67. Haselmayer P, Camps M, Liu-Bujalski L, Nguyen N, Morandi F, Head J, et al. Efficacy and Pharmacodynamic Modeling of the BTK Inhibitor Evobrutinib in Autoimmune Disease Models. *J Immunol* 2019;202(10):2888–906.
68. Joshi S, Platanius LC. Mnk kinase pathway: Cellular functions and biological outcomes. *World J Biol Chem* 2014;5(3):321–33.
69. Bai X, Wang X, Ma G, Song J, Liu X, Wu X, et al. Improvement of PD-1 Blockade Efficacy and Elimination of Immune-Related Gastrointestinal Adverse Effect by mTOR Inhibitor. *Front Immunol* 2021;12:793831.
70. Michot JM, Bigenwald C, Champiat S, Collins M, Carbone F, Postel-Vinay S, et al. Immune-related adverse events with immune checkpoint blockade: a comprehensive review. *Eur J Cancer* 2016;54:139–48.
71. Puzanov I, Diab A, Abdallah K, Bingham CO 3rd, Brogdon C, Dadu R, et al.; Society for Immunotherapy of Cancer Toxicity Management Working Group. Managing toxicities associated with immune checkpoint inhibitors: consensus recommendations from the Society for Immunotherapy of Cancer (SITC) Toxicity Management Working Group. *J Immunother Cancer* 2017;5(1):95.
72. Lin X, Deng H, Chu T, Chen L, Yang Y, Qiu G, et al. Safety and efficacy of immunotherapy rechallenge following checkpoint inhibitor-related pneumonitis in advanced lung cancer patients: a retrospective multi-center cohort study. *Transl Lung Cancer Res* 2022;11(11):2289–305.