

Access this article online

Quick Response Code:



Website:

https://eurasianj pulmonol.org

DOI:

10.14744/ejp.2024.1201

# Subcutaneous sarcoidosis masquerading as a mass

Ayşenur Atila<sup>1</sup>, Hilal Ermiş<sup>1</sup>, Servet Yolbaş<sup>2</sup>, Saadet Alan<sup>3</sup>

ORCID:

Ayşenur Atila: 0000-0002-3798-0175

Hilal Ermiş: 0000-0002-1764-9098

Servet Yolbaş: 0000-0001-8516-9769

Saadet Alan: 0000-0003-2329-151X

## Abstract:

Sarcoidosis is a multisystem granulomatous disease of unknown cause. The skin and lungs are the most commonly affected organs. While classic lesions of cutaneous sarcoidosis include a wide range of dermatological presentations, mass involvement is uncommon. A 43-year-old male presented to the orthopedic clinic with a growing mass on the right hand and wrist. A tru-cut biopsy of the lesion revealed granulomatous inflammation. However, as the mass enlarged and caused functional loss in the index finger, amputation of the finger was performed due to suspicion of malignancy, particularly a desmoid tumor. Magnetic resonance imaging demonstrated a solid, infiltrative mass with a diffuse pattern extending from the second finger to the wrist. Histopathological examination of the amputated tissue showed non-caseating granulomatous inflammation, negative for acid-fast bacilli, and no evidence of malignancy. The patient was subsequently referred to our clinic and diagnosed with sarcoidosis involving multiple organs. As local progression continued despite methylprednisolone therapy, a second surgical excision was performed, and second-line immunosuppressive therapy was initiated to control the disease. Mass formation is not a typical cutaneous manifestation of sarcoidosis. This case, featuring a suspected malignancy presenting as a hard mass in the right hand and wrist that led to amputation, demonstrates that a benign condition can progress aggressively enough to cause tissue loss. When atypical presentations occur in benign conditions like sarcoidosis, a multidisciplinary and comprehensive approach is essential to guide treatment decisions before undertaking invasive procedures.

## Keywords:

Atypical sarcoidosis, subcutaneous sarcoidosis treatment

## Introduction

Sarcoidosis is an inflammatory disease characterized by the presence of non-caseating granulomas in various organs, including the skin.<sup>[1]</sup> Cutaneous sar-

coidosis, often referred to by dermatologists as “the great imitator,” can present as non-specific reactive inflammation, such as erythema nodosum, or as subcutaneous nodules, lupus pernio, angiolupoid lesions, and macular or papular

**How to cite this article:** Atila A, Ermiş H, Yolbaş S, Alan S. Subcutaneous sarcoidosis masquerading as a mass. Eurasian J Pulmonol 2025;27:124-128.

This is an open access journal, and articles are distributed under the terms of the Creative Commons Attribution-NonCommercial-ShareAlike 4.0 License, which allows others to remix, tweak, and build upon the work non-commercially, as long as appropriate credit is given and the new creations are licensed under the identical terms.

**For reprints contact:** kare@karepb.com



Received: 03-02-2024

Revised: 29-07-2024

Accepted: 12-08-2024

Published: 27-01-2025

<sup>1</sup>Department of Chest Disease, İnönü University Faculty of Medicine, Malatya, Türkiye,

<sup>2</sup>Department of Rheumatology, İnönü University Faculty of Medicine, Malatya, Türkiye,

<sup>3</sup>Department of Pathology, İnönü University Faculty of Medicine, Malatya, Türkiye

## Address for correspondence:

Dr. Ayşenur Atila,  
Department of Chest Disease, İnönü University Faculty of Medicine, Malatya, Türkiye.  
E-mail: aysenurclk04@gmail.com

lesions.<sup>[2]</sup> Although environmental microorganisms or pathogens (e.g., *Propionibacterium acnes*, mycobacteria, *Chlamydia*) are thought to be responsible for the antigenic stimulus, or factors such as mineral dusts (e.g., silica, iron, titanium) and occupational exposures are implicated in its etiology, the exact cause of sarcoidosis remains unknown.

Subcutaneous sarcoidosis generally follows a favorable course and responds well to systemic steroid therapy. However, cases with atypical involvement that require third-line therapy, as in our case, are rare in the literature. These atypical presentations include lupus pernio, widespread erythema nodosum affecting the entire body surface, and extensive, symptomatic, and refractory osseous involvement.<sup>[3]</sup> Given the potential for atypical involvement in sarcoidosis, it is crucial to thoroughly characterize these patients to enable a prompt diagnosis and initiate effective treatment as early as possible to control the disease.

Here, we present a case of sarcoidosis manifesting as a hard cutaneous mass mimicking a malignant tumor, a presentation that has been rarely reported to date.

## Case Report

A 43-year-old male patient presented to the orthopedics clinic with swelling of the index finger and wrist of the right hand [Fig. 1]. A tru-cut biopsy taken from the solid mass revealed granulomatous inflammation [Fig. 2a].

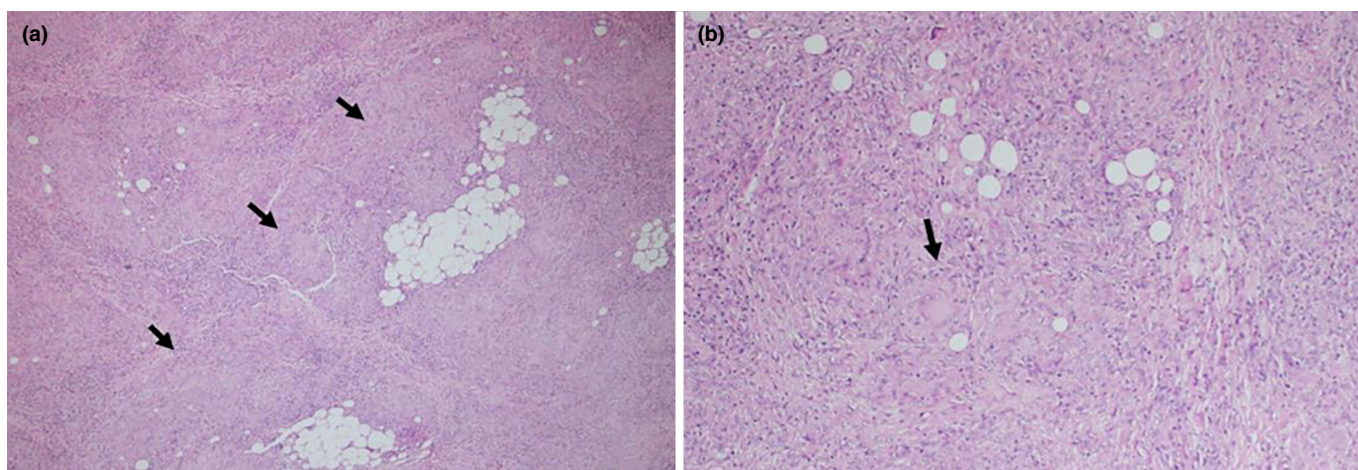
Although the initial histopathological diagnosis suggested a benign condition, further investigations were conducted as the mass on the finger continued to enlarge and was accompanied by functional loss. Magnetic resonance imaging (MRI) of the right hand and wrist demonstrated a solid, infiltrative mass with a diffuse pattern extending from the second finger to the wrist. Due to the inability to rule out a desmoid tumor, amputation of the index finger was performed [Fig. 3a]. Pathological examination of the amputated tissue showed non-caseating granulomatous inflammation, with no evidence of malignancy [Fig. 2b]. Ziehl-Neelsen staining did not detect acid-fast bacilli in the specimen.

At this stage, the patient was referred to our clinic. He had been working as an auto mechanic in his own workshop for 20 years and reported no respiratory complaints. The patient had no history of smoking, alcohol use, prior lung disease, tuberculosis (TB), or comorbidities, and there was no family history of TB.

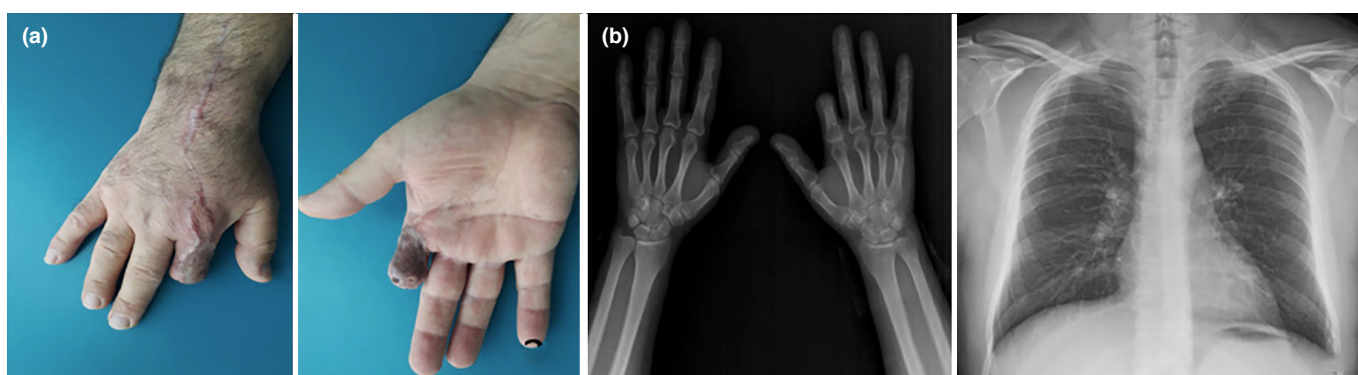
The respiratory system examination was unremarkable. Laboratory investigations, including routine biochemistry, complete blood count, C-reactive protein, antistreptolysin O, rheumatoid factor, antinuclear antibodies, serum and urine calcium levels, and respiratory function tests, were all within normal limits. The interferon-gamma release assay (IGRA) and polymerase chain reaction for TB were negative, and the tuberculin skin test was anergic. Computed tomography (CT) imaging of the thorax revealed multiple conglomer-

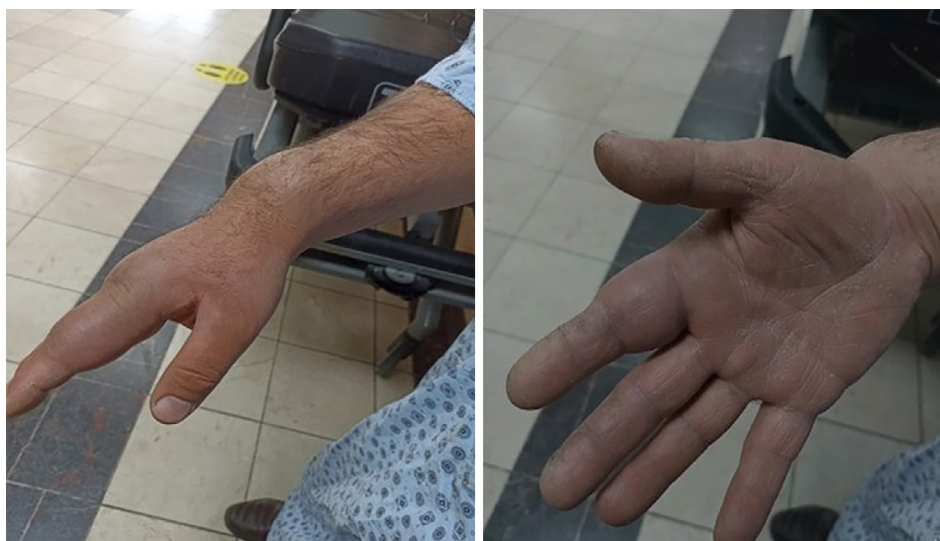

Figure 1: Swelling of the index finger and wrist of the right hand



**Figure 2:** (a) Histopathological examination of the tru-cut biopsy showing microgranuloma structures in the subcutaneous fat and connective tissue (black arrow), Hematoxylin and Eosin (H&E) stain, x40 magnification. (b) Histopathological examination of the amputated material revealing non-caseating granulomas and sparse multinucleated giant cells (black arrow), H&E stain, x100 magnification



**Figure 3:** (a) Post-amputation appearance of the second finger of the right hand. (b) Chest and right hand X-ray following anti-tumor necrosis factor (anti-TNF) treatment

erate lymphadenopathies, measuring up to 19 mm in short axis, located in the perivascular, paratracheal, subcarinal, and bilateral hilar regions. The patient's serum angiotensin-converting enzyme (ACE) level was measured at 136.3  $\mu\text{g/L}$ . No significant findings were observed in evaluations for other organ involvement. The tests for TB performed on the biopsy material were also negative. Based on radiological and laboratory findings compatible with sarcoidosis, along with granulomatous inflammation observed in the biopsy of the mass lesion, the patient was diagnosed with sarcoidosis. This diagnosis was established following a consensus reached in a multidisciplinary council involving orthopedics, rheumatology, and pulmonary medicine. Treatment was initiated with methylprednisolone at a dose of 32 mg/day. Due to increasing swelling in the wrist despite treatment, a reevaluation of the pathology specimens at a different center was performed to obtain a second opinion and rule out a possible malignancy.

The pathology results from the external center again favored a granulomatous reaction.

Due to an inadequate response to methylprednisolone and the emergence of serious side effects, including osteoporosis detected on bone densitometry, the treatment was switched to methotrexate at 10 mg/week. After eight months of methotrexate combined with low-dose corticosteroid therapy, azathioprine at 200 mg/day was introduced due to the development of a new subcutaneous nodule. During two months of azathioprine therapy, increased swelling in the hand prompted a referral to plastic surgery. A firm mass on the extensor surface of the right forearm was excised, and its histopathological examination revealed a subcutaneous sarcoidal nodule.

Following a reevaluation of all results, the patient's treatment was switched to infliximab, an anti-tumor necrosis factor-alpha (TNF- $\alpha$ ) inhibitor, at a dose of 3 mg/kg in-



travenously (i.v.) every two weeks initially. The patient is currently stable under treatment, with no further progression observed [Fig. 3b].

## Discussion

Sarcoidosis is a multisystem disease of unknown etiology, characterized by non-caseating epithelioid granulomas and presenting with a variable clinical picture depending on organ involvement. It predominantly affects the lungs, followed by the skin as the second most common site.<sup>[2]</sup> Subcutaneous sarcoidosis is a rare form of cutaneous sarcoidosis,<sup>[4]</sup> occurring in 1.4–6% of patients with systemic sarcoidosis. It typically appears at the onset of the disease and can aid in the diagnosis of systemic involvement. Subcutaneous sarcoidosis is typically a marker of non-severe systemic involvement and responds well to corticosteroid treatment. Our case is notable because the diagnosis of sarcoidosis with pulmonary involvement was established following the investigation of mass-like subcutaneous lesions. Contrary to expectations based on the literature, this case demonstrated an aggressive course. To date, only two case series of primary nodular musculoskeletal sarcoidosis have been reported in the literature.<sup>[5,6]</sup>

Epidemiological studies suggest that environmental and occupational exposures, including metals and silica, play a role in the pathogenesis of sarcoidosis.<sup>[7]</sup> Our patient had worked as a car mechanic for 20 years. Although supporting data in the literature is lacking, the aggressive granulomatous reaction in the patient's right hand and wrist raises the possibility of a direct association with metal and chemical exposure. In cases of sarcoidosis linked to occupational exposure, the primary management is the removal of the exposure. However, in this case, the patient's occupation as a car mechanic was his sole source of income, and he had no other staff to assist him in his workshop, making it impossible for him to stop working. Therefore, the patient was advised to wear a mask and gloves while working.

Subcutaneous sarcoidosis lesions can sometimes resolve spontaneously. For cases with a small number of nodules, intralesional steroid injection may lead to resolution. Systemic corticosteroids are the preferred treatment for cases without spontaneous regression or with numerous lesions.<sup>[8–10]</sup> Contrary to the existing literature, systemic corticosteroid treatment was initi-

ated as the first-line option but did not yield favorable results in our patient with multi-organ involvement, leading to disease progression and eventual organ loss. In cases that are intolerant to systemic corticosteroids, do not respond to treatment, or experience severe glucocorticoid-related side effects, alternative agents such as methotrexate, hydroxychloroquine, azathioprine, or a TNF- $\alpha$  inhibitors can be utilized.<sup>[9,10]</sup> In our patient, who developed a new sarcoid nodule on the right wrist despite steroid therapy, we escalated treatment to a TNF- $\alpha$  inhibitor as third-line therapy in accordance with international consensus guidelines.<sup>[10]</sup> The patient is currently in the third month of progression-free follow-up.

Many patients with pulmonary sarcoidosis, even without respiratory symptoms, may present with skin manifestations. However, cutaneous involvement in sarcoidosis does not always exhibit the typical lesions commonly recognized. In cases where histopathological findings suggest a benign lesion, but the clinical course appears malignant, as in this case, it is essential to adopt a multidisciplinary approach to treatment. This ensures that invasive procedures, which could result in organ loss and impact the patient's survival, are carefully considered. This case of subcutaneous sarcoidosis, presenting as a mass-like lesion, reinforces the nickname "the great imitator" often associated with this disease.

## Informed Consent

Written informed consent was obtained from the patient for the publication of the case report and the accompanying images.

## Conflicts of Interest

There are no conflicts of interest.

## Financial Support and Sponsorship

Nil.

## Use of AI for Writing Assistance

No AI technologies utilized.

## Author Contributions

Concept – A.A., H.E.; Design – A.A., H.E.; Supervision – A.A., H.E.; Materials – S.A.; Data collection &/or processing – H.E., S.Y., S.A.; Analysis and/or interpretation – A.A.; Literature search – A.A., H.E.; Writing – A.A.; Critical review – A.A., H.E.

## Peer-review

Externally peer-reviewed.

## References

1. Spagnolo P, Rossi G, Trisolini R, Sverzellati N, Baughman RP, Wells AU. Pulmonary sarcoidosis. *Lancet Respir Med* 2018;6(5):389–402. [\[CrossRef\]](#)
2. Özkan ŞA. Non infeksiyöz granülomlar. In: Tüzün Y, Gürer MA, Serdaroğlu S, Oğuz O, Aksungur VL, editors. *Dermatoloji*. 2<sup>nd</sup> edition. İstanbul:Nobel Tıp Kitapevleri;2008.p.1529–38.
3. Teles C, Teles C, Moreira S, Santos L. Rare manifestations of refractory extrapulmonary sarcoidosis. *BMJ Case Rep* 2023;16(4):e254829. [\[CrossRef\]](#)
4. Marcoval J, Maña J, Moreno A, Peyri J. Subcutaneous sarcoidosis--clinicopathological study of 10 cases. *Br J Dermatol* 2005;153(4):790–4. [\[CrossRef\]](#)
5. Ozer FL, Johnson WA, Waggener JD. Muscular sarcoidosis; a case with “tumour” formation. *Lancet* 1961;1(7167):22–4. [\[CrossRef\]](#)
6. Otake S. Sarcoidosis involving skeletal muscle: imaging findings and relative value of imaging procedures. *AJR Am J Roentgenol* 1994;162(2):369–75. [\[CrossRef\]](#)
7. Oliver LC, Zarnke AM. Sarcoidosis: An Occupational Disease? *Chest* 2021;160(4):1360–7. [\[CrossRef\]](#)
8. Dai C, Shih S, Ansari A, Kwak Y, Sami N. Biologic Therapy in the Treatment of Cutaneous Sarcoidosis: A Literature Review. *Am J Clin Dermatol* 2019;20(3):409–22. [\[CrossRef\]](#)
9. Baughman RP, Valeyre D, Korsten P, Mathioudakis AG, Wuyts WA, Wells A, et al. ERS clinical practice guidelines on treatment of sarcoidosis. *Eur Respir J* 2021;58(6):2004079. [\[CrossRef\]](#)
10. Dai C, Shih S, Ansari A, Kwak Y, Sami N. Biologic Therapy in the Treatment of Cutaneous Sarcoidosis: A Literature Review. *Am J Clin Dermatol* 2019;20(3):409–22. [\[CrossRef\]](#)