

Access this article online

Quick Response Code:



Website:

https://eurasianjipulmonol.org

DOI:

10.14744/ejp.2025.58931

The role of bronchoscopy in diagnosing granulomatosis with polyangiitis: A reminder of a recognized entity

Elif Naz Sancar¹, Aleyna Oruç², Oğuz Karcioğlu¹, Sevgen Önder², Deniz Köksal¹

ORCID:

Elif Naz Sancar: 0000-0001-5533-7397

Aleyna Oruç: 0009-0006-7834-3312

Oğuz Karcioğlu: 0000-0002-6071-0851

Sevgen Önder: 0000-0002-5523-0669

Deniz Köksal: 0000-0001-8374-3691

Abstract:

Granulomatosis with polyangiitis (GPA) is a necrotizing granulomatous small-vessel vasculitis that primarily affects the upper and lower respiratory tracts and kidneys. Diagnosis is typically confirmed through histopathological examination of tissue biopsies. Fiberoptic bronchoscopy (FOB) is a minimally invasive and effective diagnostic tool, especially in cases with endobronchial involvement. A 57-year-old male patient presented with rhinorrhea, intermittent epistaxis, headache, fatigue, and night sweats. Despite multiple courses of antibiotics for presumed sinusitis, no significant clinical improvement was observed. Although the patient had no lower respiratory tract symptoms, chest radiography revealed bilateral parenchymal infiltrates, and thoracic computed tomography (CT) showed consolidation in bilateral upper lobes and multiple nodules in peribronchovascular areas. FOB revealed increased vascularity, erythema, edema, and inflammatory lesions in the bilateral upper lobes. Forceps biopsies confirmed a necroinflammatory process due to vasculopathy, and the presence of positive cytoplasmic (c)-antineutrophil cytoplasmic autoantibodies (ANCA) supported the diagnosis of GPA. In conclusion, bronchoscopic examination is a valuable diagnostic procedure in patients, as it reveals endobronchial involvement and identifies appropriate biopsy sites.

Keywords:

Antineutrophil cytoplasmic autoantibodies (ANCA)-associated vasculitis, bronchoscopy, endobronchial involvement, granulomatosis with polyangiitis, lung

¹Department of Chest Diseases, Hacettepe

University Faculty of

Medicine, Ankara, Türkiye,

²Department of Pathology,

Hacettepe University

Faculty of Medicine,

Ankara, Türkiye

Address for correspondence:

Dr. Elif Naz Sancar,

Department of Chest

Diseases, Hacettepe

University Faculty of

Medicine, Ankara, Türkiye.

E-mail:

elifnazsancar@gmail.com

Introduction

Granulomatosis with polyangiitis (GPA), formerly known as We-

gener's granulomatosis, is a small-vessel vasculitis characterized by necrotizing granulomatous inflammation of various systemic organs and tissues. It primar-

How to cite this article: Sancar EN, Oruç A, Karcioğlu O, Önder S, Köksal D. The role of bronchoscopy in diagnosing granulomatosis with polyangiitis: A reminder of a recognized entity. Eurasian J Pulmonol 0000;00:1-5.

This is an open access journal, and articles are distributed under the terms of the Creative Commons Attribution-NonCommercial-ShareAlike 4.0 License, which allows others to remix, tweak, and build upon the work non-commercially, as long as appropriate credit is given and the new creations are licensed under the identical terms.

For reprints contact: kare@karepb.com



Received: 31.05.2025

Revised: 18.07.2025

Accepted: 29.07.2025

Published: 17-12-2025

ily affects the upper and lower respiratory tracts and kidneys.^[1,2] A positive biopsy is strongly supportive of a diagnosis of GPA, and current guidelines recommend biopsies to assist in establishing a new diagnosis of GPA.^[3] In contrast, pathological specimens obtained from active disease sites do not always provide definitive evidence of vasculitis. Renal and lung biopsies are more specific for diagnosis.^[3,4]

Fiberoptic bronchoscopy (FOB) is a minimally invasive procedure that is particularly effective in detecting the presence of endobronchial lesions. Endobronchial involvement in GPA usually presents as mucosal edema, erythema, thickening, granularity, masses, narrowing, and stenosis.^[5] Here, we present a case of GPA who initially presented with upper respiratory tract symptoms, was found to have pulmonary consolidation on imaging, and was diagnosed through biopsy of an endobronchial lesion detected by FOB.

Case Report

A 57-year-old man was admitted to our clinic with complaints of rhinorrhea, intermittent epistaxis, headache, fatigue, and night sweats. He was a non-smoker with no known comorbidities. On physical examination, his vital signs and systemic evaluations were within normal limits. The nasal passage was dry, crusted, and prone to bleeding. Laboratory investigations revealed mild anemia (hemoglobin: 11.3 g/dL) and elevated C-reactive protein (14 mg/dL), while other routine parameters and urinalysis were within normal ranges. Rheumatologic testing revealed positive antinuclear antibodies (ANA, 1/100) and cytoplasmic antineutrophil cytoplasmic antibodies (c-ANCA). Paranasal computed tomography (CT) was compatible with pansinusitis. Chest radiography showed bilateral parenchymal infiltrates, and thoracic CT scan revealed consolidation in the bilateral upper lobes and multiple nodules with irregular borders in the peribronchovascular areas of both lungs.

Nasal biopsy could not be performed due to nasal obstruction and a high risk of bleeding. Therefore, FOB was performed to evaluate the endobronchial involvement. FOB revealed vascularity, erythema, and edema in the bronchial mucosa of the bilateral upper lobes, along with inflammatory lesions but no stenosis. Figure 1 illustrates the consolidation areas in both upper lobes (a and c) and the corresponding endo-

scopic views (b and d). Interestingly, endobronchial involvement was also identified in the right lower lobe (f), despite a normal CT appearance (e). Multiple forceps biopsies were obtained from the affected areas. Histopathological examination [Fig. 2] showed wide areas of necrosis in the bronchial mucosa, the so-called dirty necrosis, or blue necrosis, showing a basophilic appearance due to the presence of nuclear debris. Necrotizing vasculitis affecting small- to medium-sized vessels was also observed, characterized by inflammatory infiltration and fibrin deposition within the vessel walls. These findings confirmed a necroinflammatory process secondary to vasculopathy and supported the diagnosis of GPA.

Discussion

Granulomatosis with polyangiitis is a systemic vasculitis that commonly affects various organs, such as the upper respiratory tract, lungs, and kidneys. Diagnosis relies on a combination of clinical presentation, laboratory tests, and radiologic findings.^[1,3] In patients with compatible clinical and radiologic features, a positive c-ANCA test strongly supports the diagnosis.^[6] However, tissue biopsy from an involved organ (generally lung, skin, or kidney) remains the gold standard for definitive diagnosis. This biopsy-based approach is recommended to confirm clinical suspicion with histopathological evidence before initiating long-term treatment with potentially toxic medications. While nasal biopsy is relatively non-invasive, it has limited sensitivity and specificity.^[7]

Lung involvement in GPA can manifest in various ways, ranging from asymptomatic to severe and fulminant, and its onset may be insidious, making it challenging to detect the disease in its early stages. Common pulmonary symptoms include coughing, hemoptysis, chest pain, and dyspnea.^[8] Radiological findings of lung involvement often include single or multiple nodules or masses. Nodules typically exhibit a diffuse pattern and may occasionally exhibit cavitation, while patchy or diffuse alveolar opacities due to capillaritis, alveolar hemorrhage, consolidation, atelectasis, and obstructive pneumonia due to bronchial stenosis can also be observed. Tracheal and subglottic stenoses are relatively rare. Pulmonary involvement can be diagnosed using percutaneous biopsy or bronchoscopic evaluation. FOB is a valuable and minimally

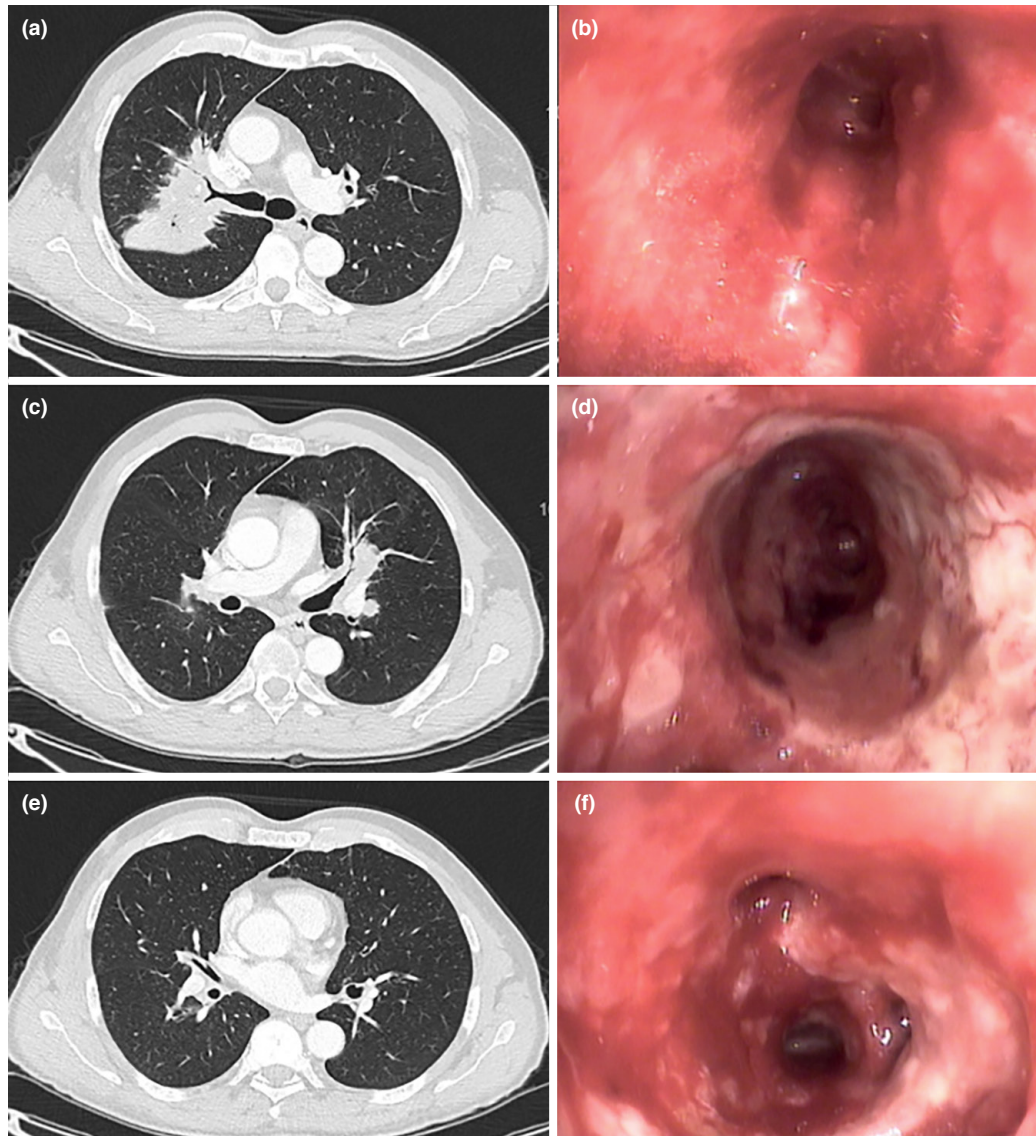


Figure 1: Computed tomography (CT) scans illustrate consolidation areas in both upper lobes (a, c) along with corresponding endoscopic views (b, d). Although the CT scan appears normal (e), the right lower lobe shows endobronchial involvement (f). The bronchial mucosa in the bilateral upper lobes and right lower lobe exhibits vascularity, erythema, and edema

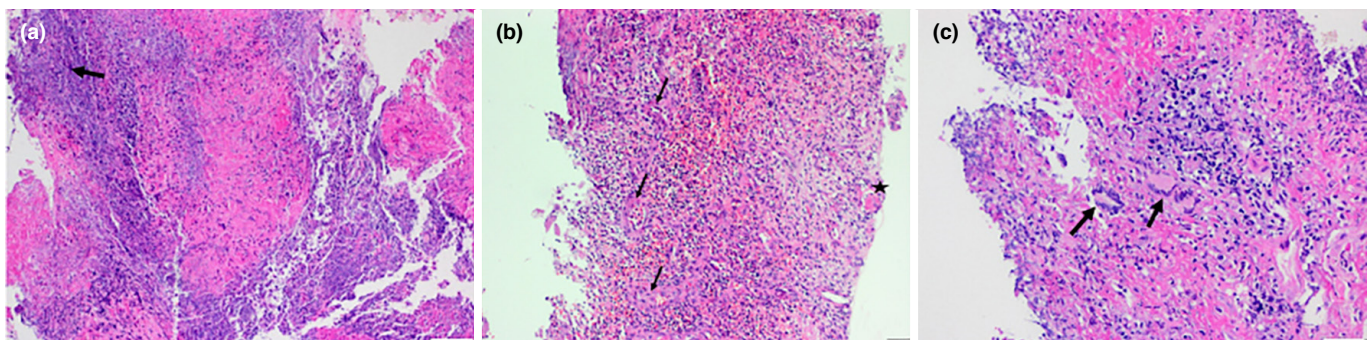


Figure 2: (a) Wide areas of necrosis with irregular borders, so-called geographic necrosis, are observed. Necrosis shows a basophilic or blue (dirty) appearance due to the presence of nuclear debris (arrow) (Hematoxylin and Eosin (H&E), x10). (b) Necrotizing vasculitis, characterized by infiltration of vessel walls with inflammatory cells (arrows) and accumulation of fibrin (asterisk), was observed in small- and medium-sized vessels (H&E, x20). (c) The inflammatory infiltrate is composed of mixed cell types, including mononuclear cells, neutrophils, eosinophils, and multinucleated histiocytic giant cells (arrows). Typical granulomas are not evident in the biopsy sample (H&E, x20)

invasive diagnostic procedure performed under conscious sedation. It allows direct visualization of the tracheobronchial mucosa and facilitates biopsies of specific areas of involvement.^[9,10]

In our case, the patient presented with predominantly upper respiratory tract symptoms but no pulmonary complaints. Thoracic CT demonstrated bilateral upper lobe consolidations and multiple nodules. FOB evaluation revealed endobronchial involvement of the GPA (vasculature, erythema, edema, and inflammatory lesions without any stenosis), and subsequent biopsies confirmed the presence of necrotizing granulomatous inflammation and vasculitis without any further invasive procedures. Furthermore, this case demonstrates that bronchoscopic examination can reveal endobronchial involvement despite an apparently normal CT scan.

Although endobronchial involvement in GPA is well known, large studies on bronchoscopic evaluation of GPA are scarce.^[8–10] A recent retrospective study investigated baseline bronchoscopy findings in patients with ANCA-associated vasculitis. Among the 31 patients with GPA, 13 (41.2%) exhibited endobronchial abnormalities. Bronchoscopic biopsy was diagnostic in six patients (50%).^[10] The low rate of diagnosis of GPA by bronchoscopic biopsy in recent studies has led clinicians away from the use of bronchoscopic evaluation and biopsy, and clinicians are increasingly turning to alternative diagnostic methods. Nasal biopsy in patients presenting with upper respiratory tract symptoms is a relatively non-invasive and easily performed procedure; however, it has inherent limitations, such as a high rate of false negatives and non-specific results.^[8]

In conclusion, GPA is a necrotizing granulomatous small-vessel vasculitis primarily affecting the upper and lower respiratory tracts and kidneys. Whenever possible, the diagnosis of GPA should be confirmed through biopsies of the affected organs or tissues, with the lungs being one of the most common sites of involvement. Although a well-known aspect of GPA, clinicians often overlook the endobronchial involvement. In patients with radiologically detected pulmonary involvement, bronchoscopic examination is a crucial diagnostic procedure as it reveals endobronchial involvement and helps identify appropriate biopsy sites.

Ethics Committee Approval

This is a single case report, and therefore ethics committee approval was not required in accordance with institutional policies.

Informed Consent

Written informed consent was obtained from the patient for the publication of this case report and accompanying images.

Conflict of Interest

The authors have no conflicts of interest to declare.

Funding

The authors declared that this study received no financial support.

Use of AI for Writing Assistance

The authors declare that no artificial intelligence (AI)-assisted technologies (such as large language models, chatbots, or image generators) were used in the preparation of this manuscript.

Author Contributions

Concept – E.N.S., O.K., D.K.; Design – E.N.S., O.K., D.K.; Supervision – O.K., S.Ö., D.K.; Resource – E.N.S., A.O., S.Ö., D.K.; Materials – E.N.S., A.O., S.Ö., D.K.; Data Collection and/or Processing – E.N.S., A.O., O.K., S.Ö., D.K.; Analysis and/or Interpretation – E.N.S., A.O., O.K., S.Ö., D.K.; Literature Review – E.N.S., A.O., O.K., S.Ö., D.K.; Writing – E.N.S., O.K., D.K.; Critical Review – E.N.S., A.O., O.K., D.K.

Peer-review

Externally peer-reviewed.

References

1. Jennette JC, Falk RJ, Bacon PA, Basu N, Cid MC, Ferrario F, et al. 2012 revised International Chapel Hill Consensus Conference Nomenclature of Vasculitides. *Arthritis Rheum* 2013;65(1):1–11. [\[CrossRef\]](#)
2. Falk RJ, Gross WL, Guillevin L, Hoffman GS, Jayne DR, Jennette JC, et al.; American College of Rheumatology; American Society of Nephrology; European League Against Rheumatism. Granulomatosis with polyangiitis (Wegener's): an alternative name for Wegener's granulomatosis. *Arthritis Rheum* 2011;63(4):863–4. [\[CrossRef\]](#)
3. Hellmich B, Sanchez-Alamo B, Schirmer JH, Berti A, Blockmans D, Cid MC, et al. EULAR recommendations for the management of ANCA-associated vasculitis: 2022 update. *Ann Rheum Dis* 2024;83(1):30–47. [\[CrossRef\]](#)
4. Maguchi S, Fukuda S, Takizawa M. Histological findings in biopsies from patients with cytoplasmic-antineutrophil cytoplasmic antibody (cANCA)-positive Wegener's granulomatosis. *Auris Nasus Larynx* 2001;28 Suppl:S53–8. [\[CrossRef\]](#)
5. Polychronopoulos VS, Prakash UB, Golbin JM, Edell ES, Specks U. Airway involvement in Wegener's granulomatosis. *Rheum Dis Clin North Am* 2007;33(4):755–75, vi. [\[CrossRef\]](#)

6. Robson JC, Grayson PC, Ponte C, Suppiah R, Craven A, Judge A, et al.; DCVAS Investigators. 2022 American College of Rheumatology/European Alliance of Associations for Rheumatology classification criteria for granulomatosis with polyangiitis. *Ann Rheum Dis* 2022;81(3):315–20. [\[CrossRef\]](#)
7. Tsuzuki K, Fukazawa K, Takebayashi H, Hashimoto K, Sakagami M. Difficulty of diagnosing Wegener's granulomatosis in the head and neck region. *Auris Nasus Larynx* 2009;36(1):64–70. [\[CrossRef\]](#)
8. Cordier JF, Valeyre D, Guillevin L, Loire R, Brechot JM. Pulmonary Wegener's granulomatosis. A clinical and imaging study of 77 cases. *Chest* 1990;97(4):906–12. [\[CrossRef\]](#)
9. Daum TE, Specks U, Colby TV, Edell ES, Brutinel MW, Prakash UB, et al. Tracheobronchial involvement in Wegener's granulomatosis. *Am J Respir Crit Care Med* 1995;151(2 Pt 1):522–6. [\[CrossRef\]](#)
10. Villeneuve T, Prévot G, Pugnet G, Plat G, Héluain V, Faguer S, et al. Role of bronchoscopy for respiratory involvement in granulomatosis with polyangiitis and microscopic polyangiitis. *ERJ Open Res* 2023;9(5):00141–2023. [\[CrossRef\]](#)